

# MEPYRAMINE MALEATE TREATMENT OF URTICARIA IN HORSES; A MULTI-CENTERED, RANDOMIZED, PLACEBO CONTROLLED, DOUBLE BLINDED CLINICAL TRIAL

**Maleato de mepiramine como tratamiento de la urticaria en caballos;  
un estudio multicéntrico, aleatorizado y controlado con placebo a doble ciego**

**Kerem Ural and Bülent Ulutas**

*Department of Internal Medicine, Faculty of Veterinary, University of Adnan Menderes, Aydin-Turkey.  
E-mail:uralkerem@gmail.com*

## ABSTRACT

The aim of the present study was to investigate the efficacy of mepyramine maleate in horses with urticaria. A total of 31 horses, between the ages of 1 and 8 years, were enrolled and randomly assigned to either a placebo or an intramuscular mepyramine maleate group. Clinical evaluations were done by the same investigator, who scored clinical healing, throughout the study and was blinded to the allocation to the groups. At the end of the trial, mepyramine maleate treatment significantly decreased ( $P<0.001$ ) the investigator's clinical scores and while weak changes were detected in the placebo treatment group. In all of the horses treated, the lesions improved gradually within 6 hours after treatment. Complete clinical remission was detected within 6 to 18 hours and all treated horses completely cured within 24 hours of starting treatment. Urticaria was still evident in 8 out of 14 untreated control horses throughout the study. No recurrency was observed in treated horses within 1 week after therapy. Results of the present study indicate that mepyramine maleate may be a safe and effective therapy for horses with urticaria.

**Key words:** Urticaria, horse, treatment, mepyramine maleate.

## RESUMEN

El objetivo del presente estudio fue investigar la eficacia del maleato de mepiramina en caballos con urticaria. Un total de 31 caballos, entre las edades de 1 y 8 años, se matricularon y fueron asignados aleatoriamente en grupos de placebo o una inyección intramuscular de maleato de mepiramina. Evaluaciones clínicas fueron realizadas por el mismo investigador, quien anotó la evolución clínica, a lo largo del estudio y la asignación

a los grupos fue hecha a doble ciego. Al final del estudio, el tratamiento con maleato de mepiramina disminuyó significativamente ( $P<0,001$ ) los resultados, mientras que cambios débiles fueron detectados en el grupo de placebo. En todos los caballos tratados, la mejoría de las lesiones se dio dentro de las 6 horas después del tratamiento. Completa recuperación clínica se detectó dentro de 6 a 18 horas y todos los caballos tratados estuvieron completamente curados dentro de las 24 horas de iniciado el tratamiento. Urticaria fue todavía evidente en 8 de los 14 caballos de control sin tratar a lo largo del estudio. No fueron observadas recaídas en los caballos tratados 1 semana después de la terapia. Los resultados del presente estudio indican que maleato de mepiramina puede ser una terapia segura y eficaz para los caballos con urticaria.

**Palabras clave:** Urticaria, caballo, tratamiento, maleato de mepiramina.

## INTRODUCTION

Urticaria, a common dermatological disorder [15], occur in horses (*Equus caballus*) of all ages [8, 13]. Although the pathophysiological mechanisms of urticaria is not very well defined in horses [6], it is characterized by dermal edema, with or without accompanying perivascular to diffuse infiltration including eosinophil and lymphocyte [12, 15], resulting from the mast cell degranulation and inflammation of the chemical mediators [15]. Urticaria may have immunological and nonimmunological background [15]. Urticaria has been suggested to be a cutaneous reaction [11] as a result of multivariable causes; mimicking reports in humanbeing [1, 17], such as immunological basis involving hypersensitivity, allergic urticaria (ie. insect bite, drug eruption, atopy and food allergy) [5-8, 15]. Nonimmunological causes include cold urticaria, exercise induced urticaria and dematographism (ie. pressure urticaria) [15].

Clinical appearance of equine urticaria presents as wheals, with acute to peracute onset, developing within minutes to hours [15], distributed bilateral and symmetrical on the trunk, neck, thorax, abdomen and extremities [8, 15]. Other rare clinical signs involve papule, giant (up to 20-40 cm diameter) or exudative wheals and gyrate/polycyclic forms [8, 15].

Clinical management of urticaria involves food elimination, intradermal skin testing and if necessary, subsequent hyposensitization therapy, and administration of corticosteroids and antihistamines. Another important point of clinical management is environmental modifications, for example, moving the horse to another location, eliminating sources of molds, removing stagnant water and stabling the horse in times when insects are known to be feeding. To the present author's knowledge, intradermal testing has not been commonly used in equine practice in Turkey. Corticosteroid treatment (i.e. prednisolone and dexamethasone) is commonly effective for controlling urticaria occurring as a result of atopy, indeed they may cause serious side effects such as laminitis, steroid induced hepatopathy and iatrogenic hyperadrenocorticism [4, 14].

Antihistamines such as hydroxyzine pamoate and doxepin hydrochloride may be used in horses with urticaria [16]. However hydroxyzine and doxepin, may both cause side effects as drowsiness and nervousness in horses [16], resulting with challenging owner compliance. Therefore, a safely used and reasonably priced antihistamine that could be used for relieving urticaria would be of significant benefit to increase owner compliance.

The first-generation antihistamines are commonly prescribed drugs relieving allergic reactions and urticaria. Mepyramine is a first generation antihistamine, blocking the peripheral histamine H(1) receptor [9]. It has been reported to cure photosensitization in lambs (*Ovis aries*) [12], acute respiratory distress in cows (*Bos taurus*) [3] and to prevent nausea and vomiting induced by xylazine in dogs (*Canis lupus familiaris*) [2]. It is commercially available in Turkey in the veterinary market. The purpose of this study was to evaluate the efficacy of mepyramine maleate for the treatment of equine urticaria in a multi-centered, randomized, placebo controlled, double blinded clinical trial.

## MATERIAL AND METHODS

### Study design

Multicentered, randomized, placebo-controlled, double-blinded clinical trial.

### Animals

A total of 31 horses with history of conventional urticaria confined to different body parts were enrolled in the present study. The horses ranged in age from 1 to 11 years. There were 17 mares, 8 stallions and 6 geldings. Breeds represented

included: 6 Thoroughbred, 5 Arabian, 5 Akhal Teke, 4 Dutch Warmblood, 4 Ponies, 3 Holsteiner and 1 of each of the following breeds: Selle Francais, Belgian Warmblood, Fresien and unknown breed.

### Allocation to treatment and owners' evaluation

Horses were randomized by coin toss, in that the side of the coin (heads=control, tails= treatment) determined the assignment of each horse. Once enrolled, horses were randomly allocated into two groups. Both owners and the investigator were blinded regarding the allocation to groups. One group, consisting of 17 horses, received intramuscular mepyramine maleate\* administration at a dosage of 2mg/kg twice at 12 hours intervals, while the other group, consisting 14 horses, received the placebo containing purified water (at equivalent doses of mepyramine maleate).

### Investigator's evaluation of clinical lesions

At the beginning and at the end of the trial (hours 0, 6, 12, 18 and 24) clinical lesions were scored by the same investigator using a scale from 0 to 3 (0 being absent, 3 being severe) (TABLE I). The used scoring system was consistently applied to all the test subjects. Clinical lesions subject to evaluation included alopecia, scaling and crusting. Areas Evaluated included head, neck, shoulder, thorax, ventral abdomen and/or whole body. The total score of each horse was the sum of the scores assigned to each clinical signs. Therefore the total score for each horse was derived from the sum of the scores of alopecia, scaling and crusting and each horse was assessed on the same lesion on every examination. Briefly the scores were averaged for each horse [i.e. if a horse had 2 areas evaluated on the nearside and only 1 on the off side, these were added and divided by 3 (2+1)] to give the horse its score for that days examination. Mean and standard deviations of score lesions regarding the mepyramine maleate group and the placebo was shown (FIG. 1). The lesion scoring was carried out by an investigator blinded to the treatment the horses had received. The signs of resolution and therefore the improvement in clinical signs associated with urticaria were scored by the same investigator. In addition throughout the study, all horses were checked daily for evidence of adverse reactions to treatment. Besides clinical follow-up was further carried out for 1 months for evaluation of possible recurrence.

Clinical recovery was deemed the resolution of dermatologic changes related to urticaria. Cure was defined when all clinico-dermatological lesions were resolved.

### Statistical analysis

Differences in the clinical score between the treatment group and the untreated placebo control group on the examination days were assessed by Mann-Whitney U test. Differences in the clinical score changes within-subject factor of time were analyzed using Wilcoxon test [10].

\* Histavet inj. flk., Vetas®, Turkey.

TABLE I

ON HOURS 0, 6, 12 AND 24 HORSES WERE GIVEN A CLINICAL SCORE AND THE SEVERITY OF URTICARIA WAS GRADED AS: OF (ABSENT =0, MILD = 1, MODERATE = 2, SEVERE = 3) ACCORDING TO THE SEVERITY TYPES. THE SIGNS OF RESOLUTION AND THEREFORE THE DISAPPEARANCE OF URTICARIA WERE SCORED BY THE INVESTIGATOR BLINDED TO THE TREATMENT THE HORSES HAD RECEIVED. THE CASES WERE RANDOMLY ASSIGNED TO EITHER MEPYRAMINE MALEATE TREATMENT GROUP (N=17) OR A PLACEBO (N=14)./ EN LAS HORAS 0; 6; 12 Y 24 CABALLOS SE LES DIO UNA PUNTUACIÓN CLÍNICA Y LA SEVERIDAD DE LA URTICARIA SE CLASIFICA COMO: DE (AUSENTE = 0, LEVE = 1, MODERADA = 2, SEVERO = 3) SEGÚN EL TIPO DE GRAVEDAD. LOS SIGNOS DE LA RESOLUCIÓN Y POR LO TANTO LA DESAPARICIÓN DE LA URTICARIA FUERON ANOTADOS POR EL INVESTIGADOR CIEGO PARA EL TRATAMIENTO QUE LOS CABALLOS HABÍAN RECIBIDO. LOS CASOS FUERON ASIGNADOS AL AZAR A CUALQUIER GRUPO DE TRATAMIENTO CON MALEATO DE MEPYRAMINA (N = 17) O UN PLACEBO (N = 14).

Groups	Hour_0				Hour_6				Day_12				Day_18				Hour_24			
	3	2	1	0	3	2	1	0	3	2	1	0	3	2	1	0	3	2	1	0
Treatment (n=17)	11	3	3	0	4	3	3	7	1	2	4	10	0	1	1	15	0	0	0	17
Placebo control (n=14)	9	2	3	0	7	3	3	1	5	3	3	3	6	2	2	4	4	2	2	6

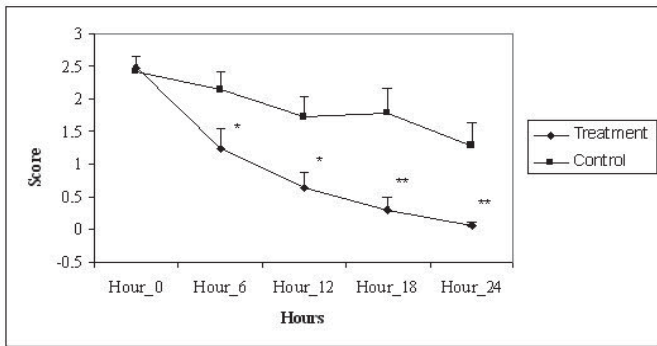


FIGURA 1. INVESTIGATOR'S CLINICAL SCORES ON HOURS 6, 12, 18 AND 24. SEVENTEEN HORSES WERE INCLUDED IN MEPYRAMINE MALEATE GROUP AND FOURTEEN IN PLACEBO GROUP. COMPARISON OF THE TWO GROUPS REVEALED THAT THE CLINICAL SCORES DID NOT DIFFER BETWEEN THE GROUPS ON HOUR 0, WHEREAS THE TREATMENT GROUP SHOWED A SIGNIFICANTLY LOWER CLINICAL SCORE THAN PLACEBO GROUP ON FROM HOUR 6 AND 12 (P<0.05) TO HOURS 18 AND 24 (P<0.001). \*INDICATES AT THE TIME AT WHICH GROUPS WERE SIGNIFICANTLY DIFFERENT. \* P<0.05, \*\* P<0.001 / RESULTADOS CLÍNICOS INVESTIGADOS EN HORAS 6; 12; 18 Y 24. DIECISIETE CABALLOS SE INCLUYERON EN EL GRUPO DE MALEATO DE MEPYRAMINA Y CATORCE EN EL GRUPO PLACEBO. COMPARACIÓN DE LOS DOS GRUPOS PUSO DE MANIFIESTO QUE LOS RESULTADOS CLÍNICOS NO FUERON DIFERENTES ENTRE LOS GRUPOS EN LAS HORAS 0, MIENTRAS QUE EL GRUPO DE TRATAMIENTO MOSTRÓ UNA PUNTUACIÓN CLÍNICA SIGNIFICATIVAMENTE INFERIOR AL GRUPO PLACEBO EN LAS HORAS DE 6 Y 12 (P<0,05) A LAS HORAS 18 Y 24 (P<0,001). \* INDICA EN EL MOMENTO EN QUE GRUPOS FUERON SIGNIFICATIVAMENTE DIFERENTES. \* P <0,05, \*\* P <0,001.

**RESULTS AND DISCUSSION**

**Clinical signs and culture results**

Among 31 horses examined, all had clinical lesions of urticaria. Accompanying skin lesions of urticarial horses were variable

(TABLE II). They often exhibited conventional forms of urticaria (24/31), and in addition giant/exudative (4/31) or polycyclic (gyrate) forms of wheals (3/31) (FIG. 2) were observed. Other less common signs included scales (14/31), crusts (9/31), papules (8/31) (FIG. 4), alopecia (12/31) and oozing (4/31). The thorax (8/31), neck (7/31), and extremities (5/31) were most commonly involved. All affected animals had normal temperature, pulse and respiration. Other body systems were also normal.

In all of the horses treated, the lesions improved gradually within 6 hours after treatment. Complete clinical remission was detected within 6 to 18 hours and all treated horses completely cured within 24 hours of starting treatment (FIGS. 3 and 5). Urticaria was still evident in 8 out of 14 untreated control horses throughout the study. No recurrency was observed in treated horses within 1 week after therapy. No adverse post-treatment reaction was observed in any of the treated animals. Further follow-up was available for 1 months duration, with no recurrency.

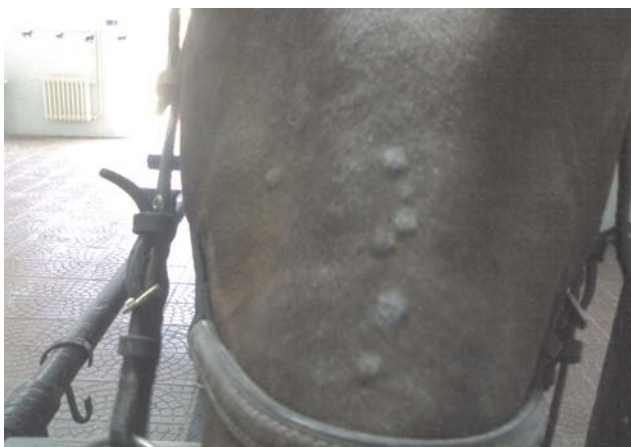**Investigator's clinical scores (FIG. 1)**

As a function of time, mepyramine maleate treated group showed significant improvement in scores from hour 6 to hours 24, while the placebo group showed weak changes in scores. Comparison of the two groups revealed that the clinical scores did not differ between the groups on hour 0, whereas the treatment group showed a significantly lower clinical score than placebo group on from hour 6 and 12 (P<0.05) to hours 18 and 24 (P<0.001).

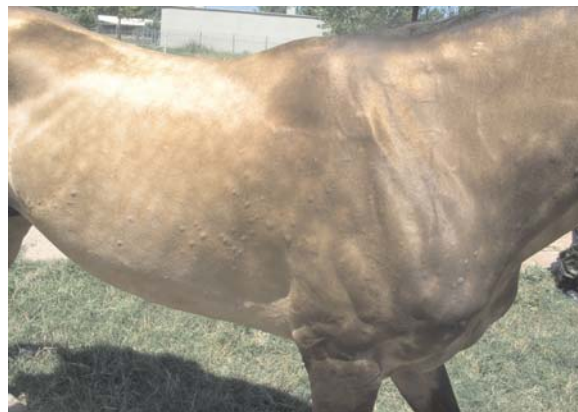In this study, mepyramine maleate treatment was found to be effective in decreasing investigator's clinical scores in horses with urticaria. The beneficial effect of the drug in this study was successful management of urticaria. In an attempt to mimic clinical practice, clinical evaluations including scoring was the main outcome measure considered in this clinical trial. The scoring system used in this study had not been previously validated, as to the present authors knowledge, because there are lack of clinical trials regarding scoring system in horses with urticaria. This scoring system, however, was purposely

**TABLE II**  
**CLINICAL BACKGROUND FOR HORSES WITH URTICARIA. N, NUMBER OF HORSES WITH THE CLINICAL SIGNS COMPARED TO THE TOTAL NUMBER OF HORSES/LOS ANTECEDENTES CLÍNICOS PARA LOS CABALLOS CON URTICARIA. N, EL NÚMERO DE CABALLOS CON LOS SIGNOS CLÍNICOS EN COMPARACIÓN CON EL NÚMERO TOTAL DE CABALLOS.**

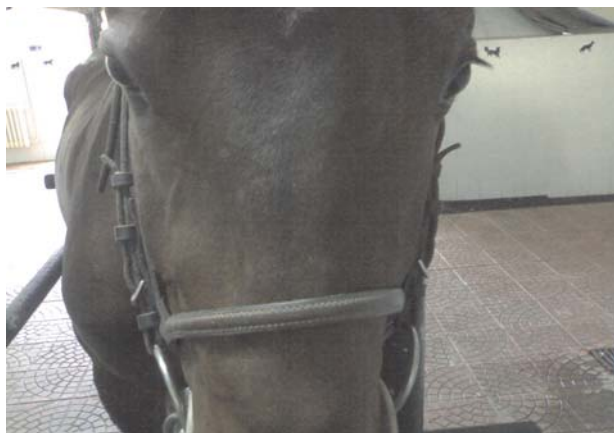Sign	N	%	Duration of clinical signs	Duration of clinical signs		Localization of lesions	Localization of lesions	
				N	%		N	%
Wheals	31/31	100	< 1 week	11/31	35	Whole body	3/31	9
-conventional	24/31	77				Head	3/31	9
-giant/exudative	4/31	12				Neck	7/31	22
-polycyclic (gyrate)	3/31	9	>4 weeks	9/31	29	Shoulder	3/31	9
Scales	14/31	45				Extremities	5/31	16
Crusts	9/31	29	recurring	4/31	12	Thorax	8/31	25
Papules	8/31	25	>4 weeks	5/31	16	Abdomen	2/31	6
Alopecia	12/31	38	>4 weeks	7/31	22			
Oozing	4/31	12	1-4 weeks	3/31	9			



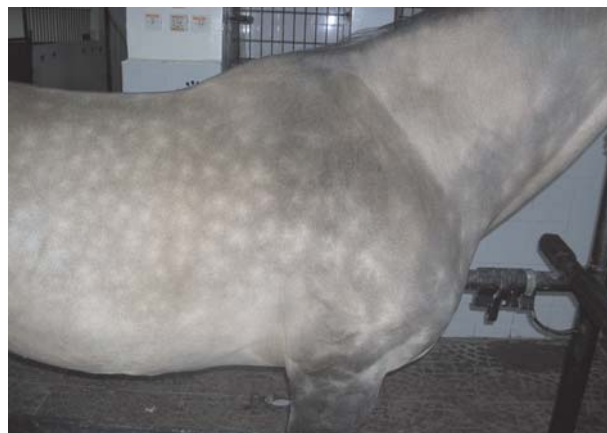**FIGURE 2. URTICARIAL WHEELS LOCATED ON THE HEAD/ RONCHAS DE URTICARIA SITUADAS EN LA CABEZA.**



**FIGURE 4. MULTIPLE WHEELS LOCATED ESPECIALLY ON THE THORAX, BEFORE TREATMENT/ MÚLTIPLES PÁPULAS ENCONTRADAS ESPECIALMENTE EN EL TÓRAX, ANTES DEL TRATAMIENTO.**



**FIGURE 3. SAME HORSE SHOWN IN FIG.2, 24 HOURS AFTER INITIAL TREATMENT. NOTICE CLINICAL HEALING AND DISAPPEARANCE OF WHEELS/ CABALLO EN LA MISMA SE MUESTRA EN LA FIGURA 2, 24 HORAS DESPUÉS DEL TRATAMIENTO INICIAL. NOTIFICACIÓN DE LA CURACIÓN CLÍNICA Y DESAPARICIÓN DE RONCHAS.**



**FIGURE 5. SAME HORSE SHOWN IN FIG.4, AFTER INITIAL MEPYRAMINE MALEATE TREATMENT, URTICARIAL LESIONS WERE DISAPPEARED IN THE HORSE ABOVE/ CABALLO EN LA MISMA SE MUESTRA EN LA FIG. 4, DESPUÉS DEL TRATAMIENTO INICIAL CON MEPYRAMINA MALEATO, LESIONES DE URTICARIA FUERON DESAPARECIDAS EN EL CABALLO, ARRIBA.**



designed to show both extent and severity of the disease and to monitor therapy. Comparison of the two groups revealed that the clinical scores did not differ between the groups on hour 0, while the treatment group showed a significantly lower clinical score than placebo group on hours 6 and 12 ( $P<0.05$ ) to hours 18 and 24 ( $P<0.001$ ).

## CONCLUSION

Treatment with mepyramine maleate resulted in a statistically significant cure on urticaria affected horses and the clinical signs resolved in every case treated. On the basis of clinical examinations, mepyramine maleate was not associated with any adverse effect. Further studies with larger numbers of horses control groups are required. It should be mentioned that urticarial diseases show minor insignificant clinical signs to systemic life-threatening condition, therefore if the underlying condition is not defined and a definitive diagnosis can not be warranted, mepyramine maleate should be the choice of medication, at least in an attempt to manage the clinical signs.

## BIBLIOGRAPHIC REFERENCES

- [1] BLAUVELT, A.; HWANG, S.T.; UDEY, M.C. II. Allergic and immunologic diseases of the skin. **J Allergy Clin Immun.** 111: 560–70. 2003.
- [2] BORKU, MK; OZKANLAR, Y; HANEDAN, B; URAL, K. Antihistaminic administration to prevent nausea and vomiting induced by xylazine in dogs. **Vet Fak Derg Uludag Univ.** 24(1/4): 99-104. 2005.
- [3] CLAUSEN, H.H.; SCHOON, H.A. Acute respiratory distress syndrome in adult cattle (Asthma syndrome) **Tier-aerztl Umschau.** 45(7):457-462. 1990.
- [4] COHEN, N.D.; CARTER, G.K. Steroid hepatopathy in a horse with glucocorticoid-induced hyperadrenocorticism. **JAVMA.** 200:1682–1684. 1992.
- [5] EVANS, A.G.; PARADIS, M.R.; O'CALLAGHAN, M. Intradermal testing of horses with chronic obstructive pulmonary disease and recurrent urticaria. **Am J Vet Res.** 53: 203–208. 1992.
- [6] FADOK, V.A. Overview of equine papular and nodular dermatoses. **Vet Clinics North Am: Equine Pract.** 11: 61–74. 1995.
- [7] FRANQUEVILLE, M.; SABBAAH, A. Chronic urticaria in sports horses. **Rev Fr Allergol.** 31: 212–13. 1999.
- [8] JOSE-CUNILLERAS, E.; KOHN, C.W.; HILLIER, A.; SAVILLE, W.J.; LORCH, G. Intradermal testing in healthy horses and horses with chronic obstructive pulmonary disease, recurrent urticaria, or allergic dermatitis. **JAVMA.** 219: 1115–1121. 2001.
- [9] LIU, B.; ZHANG, X.; WANG, C.; ZHANG, G.; ZHANG, H. Antihistamine mepyramine directly inhibits KCNQ/M channel and depolarizes rat superior cervical ganglion neurons. **Neuropharmacol.** 54:629-639. 2008.
- [10] OZDAMAR, K.; SPSS ile Biyoistatistik. Kaan Kitabevi. Eskisehir. 2003.
- [11] RÜFENACHT, S.; MARTI, E.; VON TSCHARNER, C.; DOHERR, M.G.; FORSTER, U.; WELLE, M.; ROOSJE, P.J. Immunoglobulin E-bearing cells and mast cells in skin biopsies of horses with urticaria. **Vet Dermatol.** 16 (2): 94–101. 2005.
- [12] SCHEIE, E.; FLAOYEN, A. Autumn photosensitization (alveld) in lambs. Norsk **Veterinaertidsskrift.**115(10): 651-653. 2003.
- [13] SCOTT, DW; MILLER, WH. Skin immune system and allergic skin diseases. Urticaria and angioedema. **Equine Dermatology.** St. Louis, MO, W.B. Saunders. 422– 427 pp. 2003.
- [14] VANDENABEELE, S.I.J.; WHITE, S.D.; AFFOLTER, V.K.; KASS, P.H.; IHRKE, P.J. Pemphigus foliaceus in the horse: a retrospective study of 20 cases. **Vet Dermatol.** 15:381–388. 2004.
- [15] VON TSCHARNER, C.; KUNKLE, G.; YAGER, J. Immunologic diseases. **Vet Dermatol.** 11: 163–78. 2000.
- [16] WHITE, S.D. Advances in Equine Atopic Dermatitis, Serologic and Intradermal Allergy Testing. **Clin Tech Equine Pract.** 4(4):311-313. 2005.
- [17] ZUBERBIER, T. Urticaria. **Allergy.** 58: 1224– 34. 2003.