

# Gastrointestinal foreign bodies in Dogs and Cats: (2018–2020) 32 Cases

## Cuerpos extraños gastrointestinales en perros y gatos: (2018-2020) 32 casos

Cafer Tayer İşler<sup>1\*</sup>, Ömer Kırız<sup>1</sup>, Mehmet Zeki Yılmaz Devenci<sup>1</sup>, İbrahim Alakuş<sup>1</sup>, Halil Alakuş<sup>1</sup>,  
Ziya Yurtal<sup>1</sup> and Muhammed Enes Altuğ<sup>1</sup>

<sup>1</sup>Department of Veterinary Surgery, University of Hatay Mustafa Kemal University, Hatay, Turkey.  
Email: cafer.isler@gmail.com

### ABSTRACT

Gastrointestinal foreign bodies (GFB) in cats and dogs are among the life-threatening surgical diseases that require invasive surgery. This study aimed to evaluate the cases of GFB in 32 cats and dogs diagnosed and treated in Hatay Mustafa Kemal University Veterinary Health Practice and Research Hospital. Information regarding the type, breed, age, sex, clinical symptoms, characteristics of foreign bodies (FB) localization, prognosis, type of treatment administered, and conditions determined in postoperative controls was collected. The cases were aged between 1 and 7 years and adult animals were also included. The rate of FB incident was the same in male and female cats, whereas male dogs had a higher rate of FB incident. Strings/ropes and metallic objects were the most common foreign objects found in animals. Early diagnosis and treatment were important in preventing complications in the cases, FB was usually found in the stomach, and vomiting was the most common clinical symptom. Further, surgical intervention (gastrostomy/enterotomy) was the most common treatment method with a rate of 53.13 % for treating FB in the gastrointestinal system that yielded successful results. Thus, to avoid complications and for a good prognosis, owners must be conscious and seek for diagnosis and treatment as soon as they notice the incidence of swallowing a FB, so as to ensure early diagnosis and treatment.

**Key words:** Cat; dog; enterotomy; foreign bodies; gastrostomy

### RESUMEN

Los cuerpos extraños gastrointestinales (CEG) en perros y gatos se encuentran entre las enfermedades quirúrgicas potencialmente mortales que requieren cirugía invasiva. Este estudio tuvo como objetivo evaluar los casos de CEG en 32 gatos y perros diagnosticados y tratados en el Hospital de Investigación y Práctica de Salud Veterinaria de la Universidad Hatay Mustafa Kemal. Se recogió información sobre el tipo, raza, edad, sexo, clínica, características de los cuerpos extraños (CE), localización del CE, pronóstico, tipo de tratamiento administrado y condiciones determinadas en los controles postoperatorios. Los casos tenían edades comprendidas entre 1 y 7 años y también se incluyeron animales adultos. La tasa de incidentes con CE fue la misma en gatos machos y hembras, mientras que los perros machos tuvieron una mayor tasa de incidentes con CE. Las cuerdas / mecates y los objetos metálicos eran los objetos extraños más comunes que se encontraban en los animales. El diagnóstico y tratamiento precoces fueron importantes para prevenir complicaciones en estos casos, habitualmente se encontraban CE en el estómago y el vómito era el síntoma clínico más común. Además, la intervención quirúrgica (gastrostomía / enterotomía) fue el método de tratamiento más común con una tasa del 53,13 % para el tratamiento de CE en el sistema gastrointestinal que arrojó resultados exitosos. Así, para evitar complicaciones y para un buen pronóstico, los propietarios deben estar conscientes y buscar el diagnóstico y tratamiento tan pronto como se percaten de la incidencia de la ingestión de un CE, a fin de asegurar un diagnóstico y tratamiento precoces.

**Palabras clave:** Gato; perro; enterotomía; cuerpos extraños; gastrostomía

## INTRODUCTION

The presence of foreign bodies (FB) in the gastrointestinal tract often poses life-threatening risks in cats (*Felis catus*) and dogs (*Canis Familiaris*). These FB swallowed by cats and dogs lead to obstruction or perforation in the digestive system resulting in emergency surgical treatment [12]. Gastrointestinal foreign bodies (GFB) may cause complete or partial obstruction in the digestive system. Complete obstruction leads to very severe clinical symptoms and a faster deterioration of general condition, whereas partial obstruction results in chronic digestive problems and malabsorption [7]. Further, obstructions due to FB in the gastrointestinal system may lead to gastric dilatation or volvulus [10]. Stones, plastic objects, blunt objects such as erasers, and sharp foreign objects such as strings, needles, and wires have been generally reported in cats and dogs [1, 2, 4, 9]. The clinical signs generally include recurrent vomiting, diarrhea, sudden loss of appetite, abdominal pain, abdominal swelling, dehydration, and depression [2]. An appropriate anamnesis along with clinical and radiographic examinations is required for the diagnosis of FB. Radiopaque GFB can be easily visualized on direct radiographs. Non-radiopaque FB can be detected by their shape and gas accumulation; however, this is not always possible. Positive contrast agents such as barium sulfate or iodine are used to detect obstruction or perforation caused by radiolucent FB [11]. FB are localized in the digestive system, esophagus, stomach, and small and large intestines. The most common place of obstruction is the jejunum, and the most effective treatment is enterotomy [10]. Conservative or surgical intervention can be used as the treatment method, depending on the localization of the FB and the problem it creates [7].

This study aimed to present the localization, nature, diagnosis, and treatment of FB detected in the gastrointestinal systems of cats and dogs of different breeds and sexes brought to Hatay Mustafa Kemal University Veterinary Health Practice and Research Hospital between 2018 and 2020.

## MATERIALS AND METHODS

The clinical examination, diagnosis, treatment, and prognosis of 32 cats and dogs with gastrointestinal obstruction who were brought to Hatay Mustafa Kemal University Veterinary Health Practice and Research Hospital between January 1, 2018 and October 30, 2020 were evaluated. The animals were assessed according to routine recording, anamnesis details, examination, and treatment protocol. The animals with FB detected in the entire gastrointestinal system, i.e., from the mouth to the anus, were included in the study. Information regarding the type, breed, age, sex, clinical symptoms of the animals, the duration of clinical symptoms, material of the FB, FB localization, treatment type, and postoperative processes of the animals were followed up and recorded. The duration of clinical symptoms was defined as the time elapsed from the time of occurrence of ingestion or the onset of clinical symptoms in case no swallowing was observed. The animals in whom the FB were removed from their bodies before the diagnosis were excluded from the study.

### Diagnosis

Initially, careful and detailed anamnesis was obtained from the owners of the animals. Overall, 8 of 32 (25 %) animals were brought by the owner with the information that it had swallowed a FB. Each

patient was clinically examined. The presence of FB was detected in 24 (75 %) the animals based on the clinical findings. In accordance with the obtained information and clinical findings, X-ray imaging (Intermedical, Basic 100-30®, Italy) was performed at a dose range of 75-100 kilowatts (kv) 5-10 miliamper second (mAs) to determine the topographic anatomy of the FB. FB were visualized by direct radiography in 20 (62.5 %) animals and indirectly in 12 (37.5 %) the animals. For the indirect radiographic procedure, barium sulphate (R-X suspension 100 %, Yenişehir Laboratuvarı Tic. Ve San. Ltd. Şti, Turkey) at 50 % concentration was administered to the animals with suspected or known FB and no FB opacity on direct radiography, and images were captured at 5, 15, 30, 45, 60, 75, 90, and 120 minutes (min). Overall, 12 (37.5 %) animals were examined by indirect radiography, 9 (28.13 %) by direct radiography, 6 (18.75 %) by both endoscopic examination and direct radiography, and 4 (12.5 %) by both physical imaging and direct radiographic imaging.

### Treatment and surgical technique

Surgical intervention was performed in 17 (53.13 %) of 32 animals with FB in the gastrointestinal system, whereas the FB was removed with the help of endoscopic imaging (Karl Storz, Model 69045020, Germany) in seven (21.88 %). Further, the FB was removed with medical treatment in six (18.75 %) and no procedure was performed in two (6.25 %) because the treatment was not accepted. All the animals who underwent surgery were administered 30 miligram (mg) / kilogram (kg) dose of cefazolin sodium antibiotics (cefazolin, MN Pharmaceutical Co., Turkey) 30 min before the surgery. Fluid therapy was administered to the animals with vomiting and diarrhea an hour (h) before the surgery.

For the surgery, animals were anesthetized by administering 1 mg·kg<sup>-1</sup> 2 % xylazine HCl (alfazyne 2 %; Egevet, Turkey), 10 mg·kg<sup>-1</sup> 10 % ketamine (alfamine 10 %; Egevet, Turkey). Subsequently, inhalation anesthesia (TMS, Model Future FX, Turkey) was started with isoflurane (1 - 3 % inhalation, isoflurane-USP, Piramal Critical Care Inc, USA).

All the animals were placed on their back, and the abdominal cavity was accessed through the ventral midline of the abdomen. A careful examination of the abdominal cavity was made before the organs of the digestive system were intervened. Thereafter, the topographic anatomy of the FB was determined, the area where the object was located was taken out of the operation wound, and the incision location and shape were determined. Based on the determined topographic anatomy, enterotomy was performed in 6 of 13 dogs, and gastrotomy was performed in of them 7. At the site, where the object was located, an incision was made from the intact and non-ischemic part of the organ to access the cavity of the organ from the back of the object, from the opposite direction to the movement direction of the object in the cranial section to the organ.

The object was moved back and removed from the incision area. In gastrotomy cases, the incision area was closed with an appositional pattern using double-layer sutures with schmieden and cushioning. In enterotomy cases, the area was closed with an appositional pattern using a single layer of suture. Absorbable polydioxanone (Polidiox, Boz Medical Supplies Sanayi ve Ticaret A.Ş., Turkey) suture of surgical quality was used for all applied sutures. Prior to the complete closure of the abdomen in each patient, the abdomen was washed several times with saline, and intraperitoneal penicillin G potassium (Penicillin G Potassium

1,000,000 IU, I.E. ULAGAY İlaç Sanayii TÜRK A.Ş, Turkey) was administered.

**Postoperative care and treatment**

No food was provided to the animals for at least 24 h as per the surgeon’s discretion. Oral intake could be administered in liquid form after the first 24 h. Intravenous fluids were continued until oral intake was sufficient. Antibiotics and analgesics were normally continued for at least 3 postoperative days (d). Only one patient was re-operated as a result of swallowing socks again on d 3 after the surgery. Skin stitches were removed from all the animals within 7–10 d after the surgery

**RESULTS AND DISCUSSION**

A total of 20 dogs and 12 cats from 16 different breeds were included in the study (TABLE I). Only one dog was recorded as a new case due to swallowing socks again 3 d after the surgery. The clinical symptoms included vomiting (40.62 %), diarrhea (18.75 %), salivation (18.75 %), open mouth (18.75 %), anorexia (15.63 %), inability to defecate (12.5 %), abdominal pain (12.5 %), cough (3.13 %), and bloody diarrhea (3.13 %). Further, eight (25 %) cases observed by their owners to swallow the FB had no clinical symptoms when they were brought to the hospital (TABLE II). Detailed information on the cases with FB is presented in TABLES I and II

In terms of the distribution of FB by sex, male dogs had a higher rate, whereas an equal distribution was observed between sexes in cats. Based on the sex distribution of the animals, 12 (60 %) and 8 (40 %) were male and female dogs, respectively, and 6 (50 %) and 6 (50 %) were female and male cats, respectively. In terms of breed, no FB were found in the native breeds, whereas the breeds such as American and British ones were more prone to FB incidents.

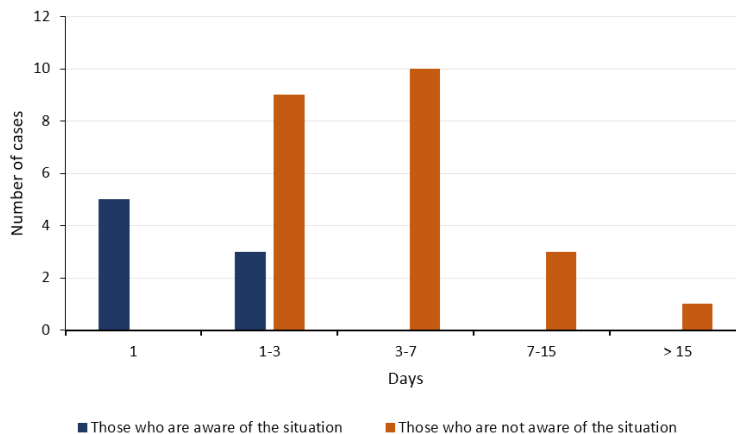
The owners of two of 20 dogs with GFB refused the proposed operative intervention after examination and diagnosis. Moreover, medical therapy was administered in two animals. Medical treatment (LAKS ENEMA Lyon Saglik Medikal Ltd. Sti, Turkey) was rectally administered via enema, and 2 % xylazine HCl (alfazyme 2 %; Egevet, Turkey) was administered for vomiting; 10 min after the administration, the FB was naturally removed from the body (stomach) by vomiting in one patient and from feces (large

**TABLE I**  
Summary of categorical information of foreign body ingestions cases

Information	Cases	Percentage
Male	19	59.38
Female	13	40.63
Acute	23	71.88
Chronic	9	28.13
Age < 1	10	31.25
Age < 1-7	17	53.13
Age > 7	5	15.63
Dog	20	62.5
Cat	12	37.5

intestine) in another. Based on the control radiographs following the treatment, it was observed that the object was not inside the animals. In all three cases, the FB was removed using forceps (Kruuse, 45 Degree Curved Forceps 220 mm, Germany) under the guidance of imaging with endoscopy. Of 13 dogs, 6 underwent enterotomy and 7 underwent gastrostomy. As one dog swallowed a FB 3 d after the surgery, it was evaluated as a new case. Further, three of 13 dogs who underwent surgical intervention had complications associated with wound infection due to disruption in post-operative dressing and treatment (TABLE II).

In terms of time elapsed from the emergence of clinical symptoms or the observation of swallowing, 27 and 4 animals were in the acute and subacute phases, respectively. The owners of 8 (25 %) animals reported that the complaint was direct FB ingestion and 19 (59 %) were not aware that the problem was associated with the ingestion of a FB; however, treatment within the first 7 d of the disease revealed that the owners were conscious, which had a positive effect on the prognosis of the disease (FIG. 1).



**FIGURE 1.** Time elapsed (d) from the emergence of clinical symptoms or the observation of swallowing vs the number of cases

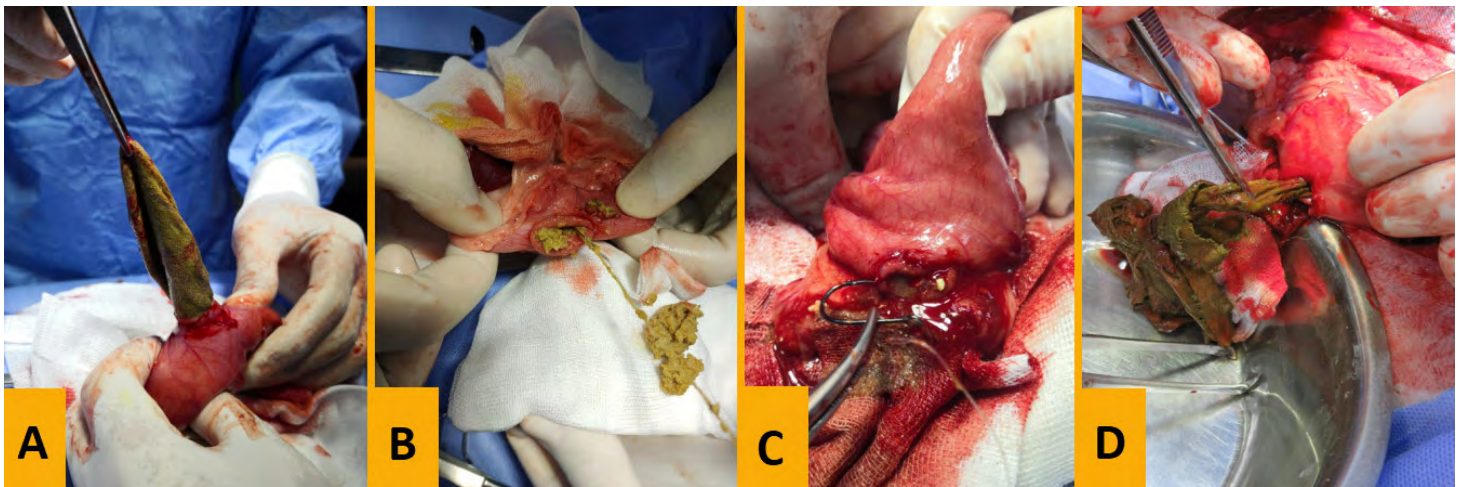
**TABLE II**  
**Summary of signalment, disease, and treatment information of foreign body ingestions cases**

N°	Species	Breed	Sex	Foreign Object	Loc.	Clinical Sign	Treatment	Prognosis
1	Cat	D-S	M	Sewing Needles	E	Salivation and Opening mouth	Endoscopy	Good
2	Cat	British	F	Bone	E	Cough and opening mouth	Endoscopy	Good
3	Cat	D-S	M	Cloth	S	Vomiting, Salivation, Anorexia	Surgical	Good
4	Cat	D-S	M	LFB - Skein	SI	Abdominal pain	Surgical	Good
5	Cat	D-S	M	LFB- Skein	SI	Vomiting and diarrhoea	Surgical	Good
6	Cat	D-S	F	Sewing Needles	E	Salivation and Opening mouth	Endoscopy	Good
7	Cat	D-S	F	Wood	S	Vomiting and diarrhoea	Surgical	Complicated
8	Cat	D-S	M	LFB-Skein	SI	Vomiting and diarrhoea	Surgical	Good
9	Cat	D-S	F	Plastic object	S	Asymptomatic	Medical	Good
10	Cat	S-F	M	Cloth	S	Vomiting and anorexia	Surgical	Good
11	Cat	S-F	F	Sewing Needles	E	Salivation and Opening mouth	Endoscopy	Good
12	Cat	S-F	F	Olive seeds	S	Asymptomatic	Medical	Good
13	Dog	B-M	F	Metallic object	S	Asymptomatic	Medical	Good
14	Dog	C-C	M	Bone	S	Vomiting and Anorexia	Surgical	Good
15	Dog	Cocker	M	Bone	LI	Hemorrhagic diarrhoea	Endoscopy	Wound infection
16	Dog	Cocker	M	Socks	S	Asymptomatic	Surgical	Good
17	Dog	Cocker	M	Socks	S	Asymptomatic	Surgical	Good
18	Dog	Crossbreed	M	LFB - Skein	S	Vomiting	Surgical	Good
19	Dog	Crossbreed	M	Metallic object	SI	No clinical Sign	Rejected	Unknown
20	Dog	Crossbreed	F	Metallic object	E	Salivation and Opening mouth	Endoscopy	Good
21	Dog	G-S	M	Cloth	S	Vomiting and no defecation	Surgical	Good
22	Dog	G-S	F	Plastic object	SI	Vomiting and diarrhoea	Surgical	Good
23	Dog	G-R	M	Stone	LI	Abdominal pain and no defecation	Surgical	Wound infection
24	Dog	G-R	F	Slipper and LFB-Skein	SI	Vomiting and no defecation	Surgical	Complicated, Wound infection
25	Dog	G-R	M	Stone	S	Abdominal pain and anorexia	Surgical	Wound infection
26	Dog	F-B	F	Fish hook and line	E	Salivation and Opening mouth	Endoscopy	Good
27	Dog	M-T	F	Fish hook and line	S	Asymptomatic	Surgical	Good
28	Dog	Pointer	F	Unknown	SI	Vomiting, no defecation, Anorexia	Rejected	Unknown
29	Dog	Pomerian	M	Metallic object	SI	Abdominal pain	Surgical	Good
30	Dog	Pug	M	Rubber	S	Asymptomatic	Surgical	Good
31	Dog	Pug	F	Electrical cable	SI	Vomiting and diarrhoea	Surgical	Good
32	Dog	Rotweiller	M	Stone	SI and LI	Vomiting and diarrhoea	Surgical	Good

D-S: Domestic Shorthair, S-F: Scottish Fold, B-M: Belgian Malinois, C-C: Cane Corso, G-S: German Shepherd, G-R: Golden Retriever, F-B: French Bulldog, M-T: Maltese Terrier Loc.: Localization, E: Esophagus, S: Stomach, SI: Small Intestine, LI: Large Intestine, LFB: Linear Foreign Body

A FB was detected in the gastrointestinal system of 12 cats. Further, two of these cats vomited after the administration of 2 % xylazine HCl (alfazyne 2 %; Egevet, Turkey), and the FB was naturally removed from their body. In four cats, the FB was removed using forceps under the guidance of imaging with endoscopy. Surgical procedures were performed in six cats. Of the 6 cats who underwent surgical intervention, enterotomy and gastrotomy were performed in 4 and two, respectively. One of 6 cats who underwent surgical intervention had complications associated with wound infection (TABLE II). Some of the FB removed during or after the surgery are shown in FIG. 2.

Gianella [6] conducted a study on the GFB in 102 dogs in 2009 and reported that the dog breeds that experienced the highest number of FB incidents included West Highland white terrier, Yorkshire terrier, Bernese mountain dog, Labrador retriever, Golden retriever, and German shepherd. In the present study, three of 20 (15 %) dogs were not of a specific breed and 17 (85 %) belonged to certain breeds [6]. Most of the dogs with FB were Golden retrievers and Germanic shepherds, consistent with the statement of Gianella [6]. A previous study reported that FB in the gastrointestinal system were more life threatening in breeds such as Staffordshire bull terriers, English bull terriers, Jack Russell



**FIGURE 2. Removal of various FB materials from the area of localization during the surgery. A: socks, B: sewing needle and thread, C: fishing rod and fishing line, and D: a piece of cloth**

**FB objects**

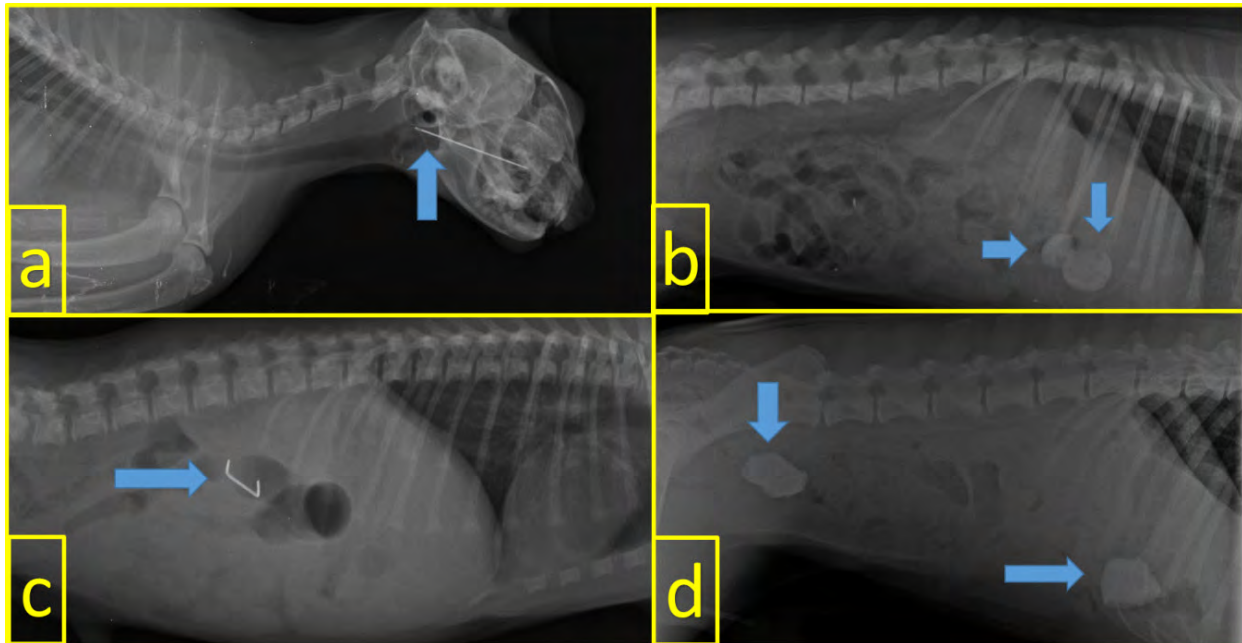
Overall, 14 different FB were detected in cats and dogs. As FB material, five (15.63 %) animals had threads or balls, four (12.5 %) had metallic objects, three (9.36 %) had stones, three (9.36 %) had sewing needles, three (9.36 %) had bones, three (9.36 %) had pieces of cloth, two (6.26 %) had plastic objects, two (6.26 %) had fishing rod and fishing line, one (6.26 %) had socks at two separate times, one (3.13 %) had an eraser, one (3.13 %) had olive seeds, one (3.13 %) had slippers, one (3.13 %) had wooden pieces, and one (3.13 %) had electrical cable. The distribution of these FB in cats and dogs is presented in TABLE III. Further, metallic objects, fishing rod and fishing line, electrical cable, slippers, socks, stones, and eraser were detected only in dogs, not in cats. Olive seeds, plastic objects, and wood fragments were among the FB detected only in cats.

**FB localization**

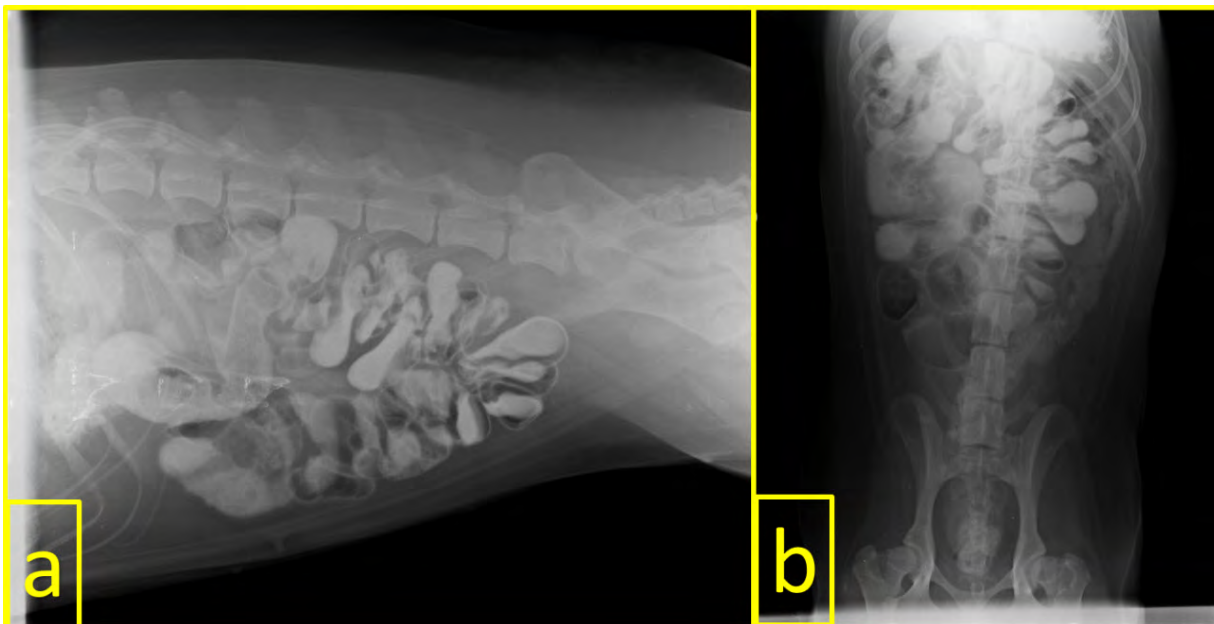
The locations of FB in the gastrointestinal system were as follows: stomach in 14 (43.75 %) animals, small intestine in 10 (31.25 %), esophagus in six (18.75 %), and large intestine in three (9.38 %). FB were detected in both small intestine and large intestines only in one patient. Some of the FB detected by radiography are shown in FIGS 3 and 4.

**TABLE III  
Foreign Body materials detected in the gastrointestinal system of cats and dogs**

Type of foreign body	Cat	Dog	Type of foreign body	Cat	Dog
Bonnet	1	2	Rubber	-	1
Cloths	2	1	Sewing needles	3	-
Electric cable	-	1	Slipper	-	1
Fish hook and line	-	2	Socks	-	2
Metallic object	-	4	Stone	-	3
Olive seeds	1	-	String/rope	3	2
Plastic object	1	-	Wood	1	-



**FIGURE 3.** Visualization of some of the Foreign Body by direct radiography. a: sewing needle in a cat, b: two erasers in the stomach in a dog, c: metallic object in a dog, and d: two stones in the stomach and large intestine in a dog



**FIGURE 4.** A typical accordion image on indirect radiography due to swallowing of a rope in a dog. a: Latero-Lateral (LL) view and b: Ventro-Dorsal (VD) view

terriers, Border collies, and Springer spaniels [7]. These breeds were not present in this study, and FB were life threatening in all the animals with complete obstruction, regardless of the breed.

In cats, FB incidents are common in domestic short-haired cats that do not belong to any specific breed [77]. Abd Elkader *et al.* reported that FB were detected in 16 Persian breed cats and 14 mixed breed cats [1]. In the present study, 8 of 12 cats were of

mixed breed, three of the remaining four cats were Scottish fold, and one was British shorthair. More comprehensive studies are required for predisposition based on breeds in the distribution of case numbers.

In 2018, Caixeta *et al.* reported that 31 (62 %) of 50 dogs that swallowed FB were male and 19 (38 %) were female [3]. Hobday *et al.* reported that 337 (67.5 %) of 499 dogs that swallowed FB

were male and 162 (32.5 %) were female. In the present study, 32 cats and dogs (19 male and 13 female) were exposed to GFB [8]. Further, 12 of 20 dogs were male (60 %) and 8 dogs were female (40 %), indicating higher rate of FB in male dogs, which is consistent with the results of Caixeta *et al.* and Hobday *et al.* [3, 8]. On the other hand, FB were found in six female (50 %) and six male (50 %) cats in the present study. Therefore, there is a need for more comprehensive studies that will demonstrate the relationship between species, breed, and sex differences, individuals affinity toward FB and animal behavior.

Fossum reported that exposure to FB generally occurs in dogs when they are puppies [5]. However, Caixeta *et al.* reported the age of dogs ingesting FB as  $5.8 \pm 4.5$ , Hobday *et al.* as  $4.27 \pm 3.51$ , Hayes as  $2.5 \pm 3.0$ , and  $1.8 \pm 1.8$  y in cats [3, 7, 8]. Thus, the age range of  $1.6 \pm 1.43$  in cats and  $4.08 \pm 3.98$  y in dogs identified in the present study is consistent with that reported in other studies [3, 7, 8] and differs from that reported by Fossum [3, 5, 7, 8]. Moreover, exposure to FB is the most common in adult cats and dogs.

FB can be diagnosed and identified by methods such as physical examination and palpation techniques, radiographic imaging, and endoscopy. Radiographic imaging can consist of a combination of direct and indirect methods (contrast radiographs). Endoscopy is a good method to identify and remove FB from the esophagus and stomach [2, 12]. In the present study, direct and indirect radiographic and endoscopic techniques were used for the diagnosis based on anamnesis details and physical examination results. The use of endoscopic examination for diagnosis and treatment is advantageous. Indirect radiography is an important diagnostic method for detecting obstruction caused by radiolucent objects without contrast images on direct radiography.

The common clinical symptoms include anorexia, vomiting, dehydration, depression, diarrhea, and abdominal pain [7, 8, 11]. In the present study, vomiting (40.62 %), diarrhea (18.75 %), salivation (18.75 %), anorexia (15.63 %), abdominal pain (12.5 %), and bloody diarrhea (3.13 %) were detected. Further, the clinical findings not reported in other studies were keeping the mouth open (18.75 %), inability to defecate (12.5 %), and cough (3.13 %) in cats that ingested needles. In addition, eight (25 %) animals were brought to the hospital without any clinical symptom after their owners witnessed them to swallow foreign bodies. Thus, the incidence of clinical findings in the present study is consistent with that reported in other studies.

Kassem *et al.* reported that complications are rare in cases of FB, whereas Gianella reported a complication rate of 12.74 %, and Hayes reported a complication rate of 80 % [6, 7, 10]. Yurdakul reported that intestinal hyperemia, congestion, and intestinal contents flowed into the abdominal cavity in cases of FB [14]. Hayes reported that in cases of 14 d or more, the prognosis was poor, the risk of peritonitis increased, and in some cases, the euthanasia option was used [7]. In the present study, as most of the animals were treated in the subacute and acute phases, no complications were observed. Only 3 of 23 (9.68 %) animals had wound infection due to the lack of post-operative dressing and antibiotic treatment. Thus, the prognosis was overall good.

Some studies have reported the presence of FB such as latex teat, plastic/rubber objects, string/rope/fishing lines, stones, balls, underwear/nappy, corn-cob, leather, metallic objects/coins, bones,

cassette tapes, needles and threads, fish hooks and lines, plastic bags, blankets, electric cables, peach stones, wooden skewers, potatoes, pine cones, beads, lolly sticks, marble, and glass objects in the digestive system of cats and dogs [3, 6, 7, 10]. Similar FB were found in the present study; however, no socks, cloth, or olive seeds were found in the previous studies.

Hayes reported that FB were mostly detected in the small intestine [7]. In the present study, FB the gastrointestinal system were mostly detected in the stomach (43.75 %) and small intestines (31.25 %). The least common regions for FB were esophagus (18.75 %) and large intestines (9.38 %). Thus, these results are inconsistent with the results of the studies by Hoffmann, Veeder and Taylor, Kassem *et al.*, and Caixeta *et al.* [3, 9, 10, 13]. The higher number of stomach cases in the present study can be associated with early diagnosis.

## CONCLUSIONS

The ingestion of FB is more common in adult cats and dogs aged between 1 and 7 y, the ingestion of strings/ropes and metallic objects as FB is more common, and it is important that owners notice the incident for early diagnosis and treatment to ensure prevention of complications. Thus, this study shows that FB are mostly found in the stomach and vomiting is the most common clinical symptom.

## CONFLICT OF INTEREST

The authors declare that they have no conflicts of interest in the research.

## BIBLIOGRAPHIC REFERENCES

- [1] ABD ELKADER, NA; EMAM, IA; FARGHALI, HA; SALEM, NY. Oesophageal FB in cats: Clinical and anatomic findings. **Plos One**. 15: 1-15. 2020.
- [2] BEBCHUK, TN. Feline gastrointestinal foreign bodies. **Veterinary Clinics. J. Small Anim. Pract.** 32: 861-880. 2002.
- [3] CAIXETA, ACF; ALVES, EGL; COELHO, NGD; SOUZA, ACF; TORRES, RCS; NEPOMUCENO, AC. FB in the gastrointestinal tract of dogs: A retrospective study. **Ars. Vet.** 34: 20-24. 2018.
- [4] DEN HERTOOG, E. Endoscopic removal of FB from cats or dogs. **Tijdschr Diergeneeskd.** 128: 434-439. 2003.
- [5] FOSSUM, TW. Surgery of the Digestive System. Cap 20. **Small Animal Surgery**. Fossum, TW. (Ed), 4th Ed. Elsevier Health Sciences, St Louis, US. Pp. 386-583. 2014.
- [6] GIANELLA, P; PFAMMATTER, NS; BURGNER, IA. Oesophageal and gastric endoscopic FB removal: complications and follow - up of 102 dogs. **J. Small Anim. Pract.** 50: 649-654. 2009.
- [7] HAYES, G. Gastrointestinal FB in dogs and cats: a retrospective study of 208 cases. **J. Small Anim. Pract.** 50: 576-583. 2009.
- [8] HOBDAY, MM; PACHTINGER, GE; DROBATZ, KJ; SYRING, RS. Linear versus non - linear gastrointestinal FB in 499 dogs: clinical presentation, management and short - term outcome. **J. Small Anim. Pract.** 55: 560-565. 2014.

- [9] HOFFMANN, KL. Sonographic signs of gastroduodenal linear FB in 3 dogs. **Vet. Radiol. Ultrasound.** 44: 466-469. 2003.
- [10] KASSEM, MM; EL-KAMMAR, MH; EL-MENSHAWEY, MF. Surgical Management of FB in Stomach and Intestine of Some Foreign Breed Dogs. **Alexandria J. Vet. Sci.** 42: 11-15. 2014.
- [11] PAPAZOGLU, LG; PATSIKAS, MN; RALLIS, T. Intestinal FB in dogs and cats. **Compend. Contin. Educ. Vet.** 25: 830-845. 2003.
- [12] TYRRELL, D; BECK, C. Survey of the use of radiography vs. ultrasonography in the investigation of gastrointestinal FB in small animals. **Vet. Radiol. Ultrasound.** 47: 404-408. 2006.
- [13] VEEDER, CL; TAYLOR, DK. Injury related to environmental enrichment in a dog (*Canis familiaris*): Gastric foreign body. **J. Am. Assoc. Lab. Anim. Sci.** 48: 76-78. 2009.
- [14] YURDAKUL, I. Intestinal Perforation Due to Gunshot Injury in a Kangal Dog. **CUSBED.** 2: 1-8. 2017.