

Protective effect of *Helichrysum plicatum* on head shock protein inflammation and apoptosis in Gentamicin induced nephrotoxicity

Efecto protector de *Helichrysum plicatum* sobre la inflamación de la proteína de choque térmico y la apoptosis en la nefrototoxicidad inducida por gentamicina

Ismail Bolat¹, Kubra Asena Terim-Kapakin^{1*}, Betül Apaydin Yıldırım², Esra Manavoglu Kirman¹

¹Atatürk University, Faculty of Veterinary Medicine, Departments of Pathology, Erzurum, Türkiye.

²Atatürk University, Faculty of Veterinary Medicine, Departments of Biochemistry, Erzurum, Türkiye.

*Corresponding Author: kubra.terim@atauni.edu.tr

ABSTRACT

Gentamicin (GM) is an aminoglycoside antibiotic the most common used in the treatment of infectious diseases in humans and animals. However, GM causes damage to many tissues and organs in the body, especially the kidneys. *Helichrysum plicatum* (Hp), native to the Balkans and Anatolia, is a plant used in various diseases such as diabetes, liver and kidney damage. In this study, Male Sprague Dawley rats (n=36 and 200–250 g) were randomly divided into 6 experimental groups: Group 1: Control; received normal saline (intraperitoneally -i.p.-), Group 2: Hp (100 mg·kg⁻¹ day i.p.), Group 3: Hp (200 mg·kg⁻¹ day i.p.), Group 4: GM (80 mg·kg⁻¹ day i.p.), Group 5: GM 80 + Hp 100 (mg·kg⁻¹ day i.p.), and Group 6: GM 80 + Hp 200 (mg·kg⁻¹ day i.p.). Then kidney tissue samples were collected for evaluations. All of our results showed that Hp (100 mg·kg⁻¹ day) reduced the levels of pro-inflammatory cytokines such as IL-8, IL-6, and TNF- while increasing the level of anti-inflammatory cytokine IL-10. It was also observed that Hp reduced the expressions of the caspase3, NOS and Heat shock proteins such as Hsp27 and Hsp70. With this study, we have shown that Hp probably due to its chemical properties has a protective effect against GM induced nephrototoxicity by reducing the values stated above to normal values.

Key words: Caspase; gentamicin; *Helichrysum plicatum*; HSP; kidney; NOS

RESUMEN

La gentamicina (GM) es un antibiótico aminoglucósido de los más utilizados en el tratamiento de enfermedades infecciosas tanto en humanos como en animales. Sin embargo, la GM causa daños en muchos tejidos y órganos del cuerpo, especialmente en los riñones. *Helichrysum plicatum* (Hp), originaria de los Balcanes y Anatolia, es una planta utilizada en diversas enfermedades como la diabetes y los daños hepáticos y renales. En este estudio, se utilizaron ratas machos Sprague Dawley (n=36 y 200–250 g) las cuales se dividieron aleatoriamente en 6 grupos experimentales: Grupo 1: Control; recibieron solución salina normal (vía intraperitoneal -i.p.-), Grupo 2: Hp (100 mg·kg⁻¹ día i.p.), Grupo 3: Hp (200 mg·kg⁻¹ día i.p.), Grupo 4: GM (80 mg·kg⁻¹ día i.p.), Grupo 5: GM 80 + Hp 100 (mg·kg⁻¹ día i.p.), y Grupo 6: GM 80 + Hp 200 (mg·kg⁻¹ día i.p.). A continuación, se recogieron muestras de tejido renal para su evaluación. Todos nuestros resultados mostraron que Hp (100 mg·kg⁻¹ día) redujo los niveles de citoquinas proinflamatorias como IL-8, IL-6, y TNF-α, mientras que, aumentó el nivel de citoquina antiinflamatoria IL-10. También se observó que la Hp reducía las expresiones de la caspasa3, la NOS y las proteínas de choque térmico como la Hsp27 y la Hsp70. Con este estudio, hemos demostrado que la Hp probablemente debido a sus propiedades químicas tiene un efecto protector contra la nefrototoxicidad inducida por GM reduciendo los valores arriba indicados a valores normales.

Palabras clave: Caspasa; gentamicina; *Helichrysum plicatum*; HSP; riñón; NOS

INTRODUCTION

Aminoglycosides are a group of antibiotics which are usually used for treatment of critical and dangerous infections particularly caused by gram-negative and some gram-positive bacteria. Gentamicin (GM) is an aminoglycoside antibiotic the most common used in the treatment of infectious diseases in humans and animals [1, 2, 3]. However, they have serious side effects such as ototoxicity [1], nephrotoxicity [2, 3, 4, 5, 6, 7], hepatotoxicity [4, 8, 9, 10, 11], neuromuscular blockade, and allergic skin reactions [1] depending upon the dosage. The mechanisms by which gentamicin (GM) induces tissue damage are not fully explained, but links to the formation of reactive oxygen species (ROS), inflammation, and activation of the apoptotic pathways [2, 3, 6, 9, 11, 12, 13]. Despite the introduction of the new generations of antibiotics recently, aminoglycosides are still used in various clinical situations due to their inexpensive and high efficacy [1, 2, 3]. Heat shock proteins (Hsps) are known as a group of proteins that can always be produced in the body and act as a protector in the organism in various inflammation and oxidative stress situations [2, 3]. These proteins have an important place in the intracellular and extracellular defense mechanism in kidney tissue [14, 15, 16]. In various toxicity studies, protective effects of HSPs in kidney tissue against toxicity have been demonstrated [17, 18].

Many natural products have been used to preserve the tissues from toxicities caused by GM [3, 6, 8, 12, 19, 20] through neutralizing the reactive species and enhancing the antioxidant defense. Sandy everlasting or immortelle flower (*Helichrysum plicatum*) (Hp) is an herbaceous plant, which is natural to the Balkans, Anatolia. It has been used in folk medicine for various diseases such as diabetes, liver and kidney damages. Its urolitic, nephroprotective, antihyperglycemic, antioxidant, antimicrobial, hepatoprotective, and cytotoxic effect [4, 21, 22, 23] are related to presence of flavones, flavanones, flavonols and kalones [21, 23, 24].

In this study, we targeted to demonstrate the relationship between Hsp27, Hsp70, caspase-3, NOS, and cytokines expressions in protective effects of *Helichrysum plicatum* (Hp) on gentamicin induced nephrotoxicity using biochemical, histopathological, immunohistochemical and immunofluorescence methods.

MATERIALS AND METHODS

Experimental Animals and Design

Male Sprague Dawley rats (*Rattus norvegicus*) (200–250 g) were obtained from Experimental Application and Research Institute. These rats were housed at normal temperature of (22 ± 2°C), and 12/12 hours (h) light/dark cycle. The rats were fed *ad libitum* for 7 days (d) and their adaptations were achieved. Then, experiments were applied to rats for 8 d [4]. Gentamicin sulphate was purchased from Eczacıbasi (Istanbul, Turkey). All other chemicals of analytical grade were bought from the Sigma Chemical Co. (St. Louis, MO). *Helichrysum plicatum* specimens were collected in Bayburt, and identified at Department of Botany. A voucher specimen was kept at the Herbarium of Atatürk University (Voucher Number ATA9562/2013), Erzurum (Turkey) [4]. The experiment was conducted according to the ethical conditions confirmed by the Ethical Rules of Experimental Animal Teaching and Researcher Center, 25240 Erzurum, Turkey. [Ethical Approval Number: 36643897-932140].

Preparation of the Test Samples

The dried Hp samples were dusted in a crusher machine (SINOMTP, Mobile impact crusher, Shandong, China) and then 100 g of Hp was extracted one by one within 500 mL ethanol for 2 days at 21 ± 2°C. The extract was filtered and evaporated to dryness in a vacuum (Biomec, ECO370, Türkiye) under reduced pressure at 40°C with a evaporator (IKA, RV 05, Türkiye). These extracts obtained were stored (Arçelik, 4252 EY, Türkiye) at 4°C. It was prepared according to method described in our previous study [4].

Experimental Protocol

Male Sprague Dawley rats (n=36) were randomly divided into 6 experimental groups: Group 1: Control. Received normal saline (intraperitoneally -i.p.-); Group 2: Hp (100 mg·kg⁻¹ day i.p.); Group 3: Hp (200 mg·kg⁻¹ day i.p.); Group 4: GM (80 mg·kg⁻¹ day i.p.); Group 5: GM + Hp 100 (mg·kg⁻¹ day i.p.); and Group 6: GM + Hp 200 (mg·kg⁻¹ day i.p.). Administration was done for 8 days and then rats were sacrificed with pentobarbital sodium (60 mg·kg⁻¹ i.p.) under anesthesia. The kidney tissue samples were taken for evaluations biochemically, histopathologically immunohistochemically and immunofluorescence. Then, the kidney tissue samples were stored at -80°C for biochemical analysis.

Kidney tissues homogenization for ELISA and cytokines levels determination by

The kidney tissues were homogenized in a Qiagen Tissue Lyser II homogenizer using a buffer of 0.1 M phosphate buffer (pH 7.4) to obtain a 1:10 (w/v) homogenate. The tissues homogenate preparation method required for all ELISA (enzyme-linked immunosorbent assay) kits have been given in our previous study [4]. The supernatant obtained was used for Interleukin 6 (IL-6), Interleukin 8 (IL-8), Interleukin 10 (IL-10), and Tumor necrosis factor alpha (TNF-α) analyzes. The IL-10, IL-6, IL-8 and TNF- levels were analyzed in the kidney using an ELISA according to the manufacturer' instructions (Epoch, BioTek; Winooski, VT, USA) commercially.

Histopathological examination

For histopathological and immunohistochemical examinations, the tissue samples were fixed with 10% neutral buffered formalin for 48 h. Then, the samples were dehydrated through alcohol series, cleared with xylene and embedded in paraffin blocks. After routine procedures, sections of 4–5 μm thickness were cut (LEICA RM2255, Germany) and mounted onto slides. At last, the sections were stained with Hematoxylin and Eosin (H&E) and Periodic Acid Schiff (PAS), and examined under a light microscope (OLYMPUS BX51, Japan) [25].

Immunohistochemical examination

The sections washed with phosphate buffered saline (PBS) were incubated (BINDER ED 56, Germany) with polyclonal rabbit Hsp27 antibody (clone: ab78806, dilution 1/100; Abcam, UK), Hsp70 (clone: sc66036, Santa Cruz Biotechnology, dilution 1/200), and caspase-3 (clone: ND 600-1235, Novus Biological, USA, diluted 1:200) at 37°C for 30 min. Immunohistochemical analysis was carried out as recommended by the manufacturer [Abcam, UK, HRP Detection IHC Kit (Catalog No: ab80436)] and 3,3'-diaminobenzidine (DAB, Dako Cytomation) was used as the chromogen. Ground staining was achieved with Mayer's hematoxylin [26, 27].

Immunofluorescence examination

The sections washed with phosphate buffered saline (PBS) were incubated (BINDER ED 56, Germany) with NOS antibody (clone: sc-7271, dilution 1/100, US), at 37°C for 30 min. Then, secondary fluorescent antibody (FITC, clone: ab6717 Dilution Ratio: 1/500, UK) was dropped and incubated for 45 min. The washed sections were covered with a coverslip with a mixture of glycerine and distilled water (1/9) and examined under a fluorescent microscope (ZEISS AXIO, Germany). Hsp70, Hsp27, Caspase-3, NOS positivity were scored as follows: none (-), mild (+), moderate (++) , severe (+++), more severe (++++), and images were taken [26, 27].

Statistical analysis

The data obtained were evaluated statistically using the GraphPad Prism Version 8.0.2 statistical package program. The mean, standard error, and median values of the data were determined using the Descriptive Statistics–Explore test. The nonparametric Kruskal–Wallis test was used to determine whether there was a statistical difference between the parameters and the data obtained from the groups. *P* values less than 0.05 were evaluated significant.

RESULTS AND DISCUSSION

Biochemical findings

Levels of renal cytokines TNF- α , IL-6, and IL-8 were detected an increase in the GM group while IL-10 level was found a decrease as compared to the control group (*P*<0.05). It was observed that TNF- α , IL-6, and IL-8 levels were significantly a decrease whereas IL-10 level was an increase in all experimental groups treated with Hp. However, in the group treated with GM + Hp100 (mg·kg⁻¹ day i.p.) TNF- α , IL-6, IL-8, and IL-10 levels were observed to reach levels similar to the control group (*P*<0.05). TABLE I summarized renal cytokines levels results.

Histopathological findings

Histopathological changes in the kidney tissues of all the experimental groups are demonstrated in FIG. 1. Histopathological changes were not observed in the kidney tissues in the control group. In the GM group there were very severe tubular epithelial degeneration and

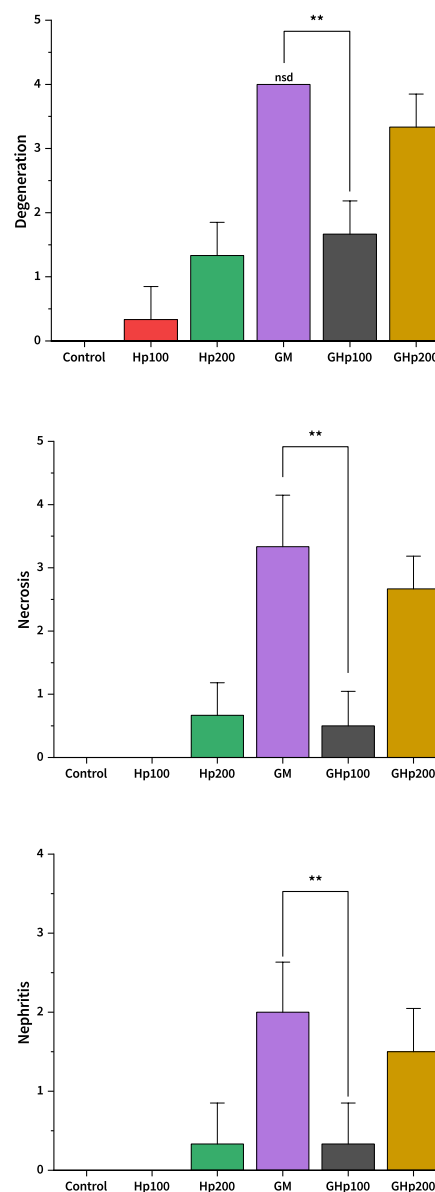


FIGURE 1. Histopathological changes in the kidney tissues of all the experimental groups. Degeneration (**, *P*=0.0022); Necrosis (**, *P*=0.0022); Nephritis (**, *P*=0.0065). (n=6) (nsd=no standard deviation)

TABLE I
The levels of IL-10, IL-6, IL-8, and Tnf- in the kidney tissues of all the experimental groups

Groups	IL-10 (pg·mg ⁻¹)	IL-6 (pg·mg ⁻¹)	IL-8 (pg·mg ⁻¹)	Tnf- α (pg·mg ⁻¹)
1: Control	30.54 ± 0.21 ^a	131.24 ± 0.32 ^c	86.67 ± 0.50 ^d	1.33 ± 0.01 ^{cd}
2: Hp100	30.42 ± 0.20 ^a	130.86 ± 0.40 ^c	86.70 ± 0.32 ^d	1.31 ± 0.00 ^d
3: Hp200	29.60 ± 0.25 ^a	131.00 ± 0.28 ^c	87.45 ± 0.33 ^d	1.34 ± 0.01 ^c
4: GM	14.86 ± 0.25^e	371.69 ± 1.81^a	187.07 ± 0.31^a	2.33 ± 0.01^a
5: GM+Hp100	29.31 ± 0.18 ^a	132.66 ± 0.35 ^{bc}	94.70 ± 0.94 ^e	1.31 ± 0.00 ^d
6: GM+Hp200	23.18 ± 0.85 ^b	135.86 ± 0.75 ^b	98.62 ± 0.20 ^b	1.37 ± 0.00 ^b
<i>P</i>	***	***	***	***

The results were expressed as mean ± standard error means (SEM) for 6 rats in each group. Different lowercase letters (a-d) in the same row indicate significant difference among each group (*P*<0.05). The lowest value is marked with "a" and the sign letter is changed gradually when the statistical difference occurs IL-8, IL-6, Tnf- α , and IL-10

necrosis, and severe lymphocyte and macrophage cells in intertubular regions. In addition, intratubular hyaline cast and enlargement of the bowman capsule were seen in the kidney tissues. In the GM+Hp200 group there were severe tubular epithelial degeneration and necrosis, and severe lymphocyte and macrophage cells in intertubular regions, and intratubular hyaline cast. In the GM+Hp100 group there were mild tubular epithelial degeneration and necrosis. In the Hp200 group there were moderate tubular epithelial degeneration and necrosis, and mild lymphocyte and macrophage cells in intertubular regions. In the Hp100 group there were mild tubular epithelial degeneration (FIG. 2).

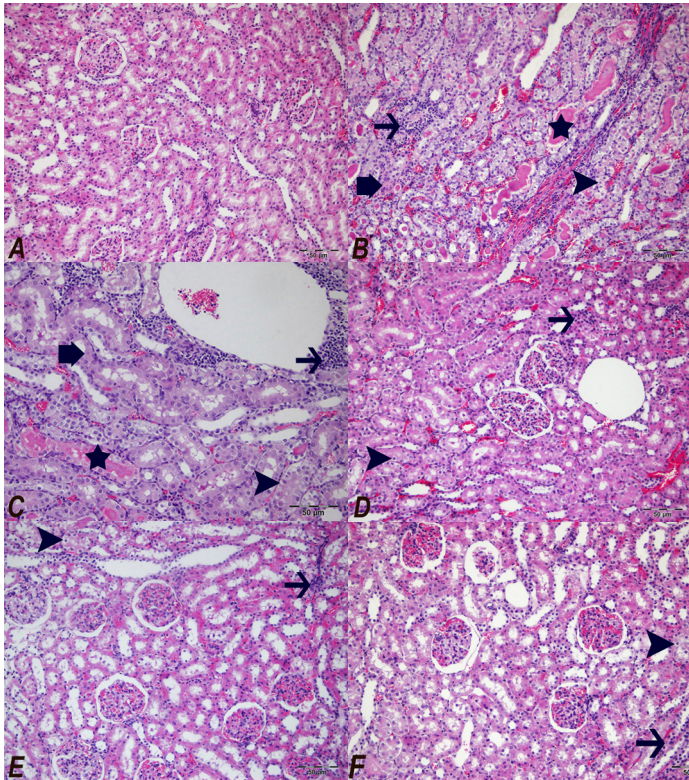


FIGURE 2. Histopathological view of the kidney tissues H&E, Bar: 50 μ m, A: Control group, B: GM group, C: GM+Hp200 group, D: GM+Hp100 group, E: Hp200 group and F: Hp100 group. Degeneration in tubular epithelium (arrow head), lymphocyte and macrophage cells infiltration in intertubular regions (arrow), and hyaline casts (star) and PAS staining (Above plate B, Bar: 20 μ m)

Immunohistochemical findings

Hsp27 and Hsp70 levels in the kidney tissues of all the experimental groups are demonstrated in FIG. 3. The Hsp27 (FIG. 4) and Hsp70 (FIG. 5) expressions were seen in the kidney tubular epithelial cells, renal mesangial cells, and endothelial cells of blood vessels in all experimental groups. However, high expression levels were observed in the groups GM and GM+Hp200 whilst low secretion levels in the control group were observed. The mildest expressions Hsp27 and Hsp70 were detected in the GM+Hp100 group. Caspase-3 levels in the kidney tissues of all the experimental groups are demonstrated in FIG. 3. The expression of caspase-3 (FIG. 6) were showed in the kidney mesangial cells, epithelial cells of kidney tubules and endothelial cells of blood vessels, as well as inflammatory cells. A stronger expressions were observed in the GM and GM+Hp200 groups than the other groups, the weak expression was in the control group ($P < 0.05$). The mildest caspase-3 expression was detected in the GM+Hp100 group.

Immunofluorescence findings

NOS levels in the kidney tissues of all the experimental groups are demonstrated in FIG 7. The NOS expressions (FIG. 3) were seen in the kidney tubular epithelial cells, renal mesangial cells, and endothelial cells of blood vessels in all experimental groups. However, high expression levels were observed in the groups GM and GM+Hp200 whilst low secretion levels in the control group were observed. The mildest expressions NOS were detected in the GM+Hp100 group. The NOS expression were decreased in Group GM+Hp100 when

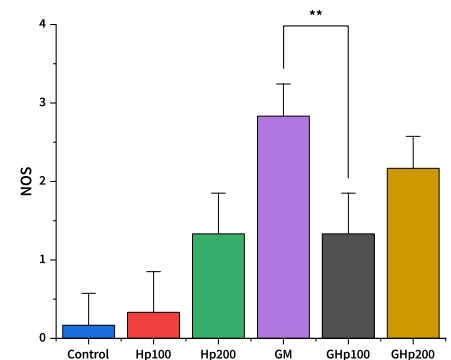
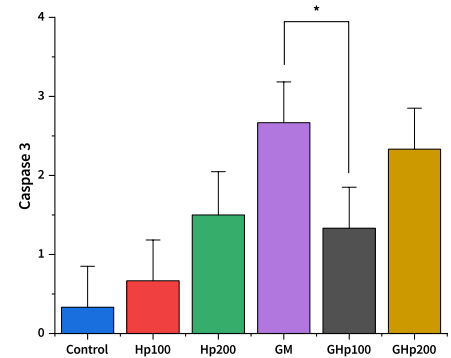
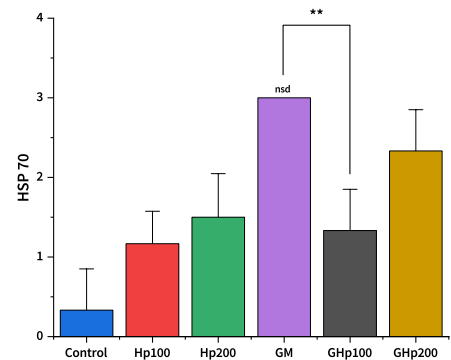
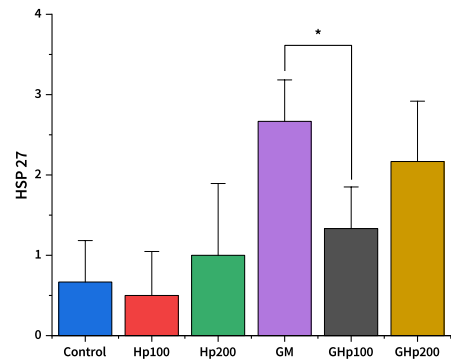


FIGURE 3. Hsp 27, HSP 70, Caspase 3 and NOS level in the kidney tissues of all the experimental groups. HSP 27 (*, $P=0.0130$); HSP 70 (**, $P=0.0022$); Caspase 3 (*, $P=0.0130$); NOS (**, $P=0.0065$) ($n=6$, (nsd=no standard deviation)

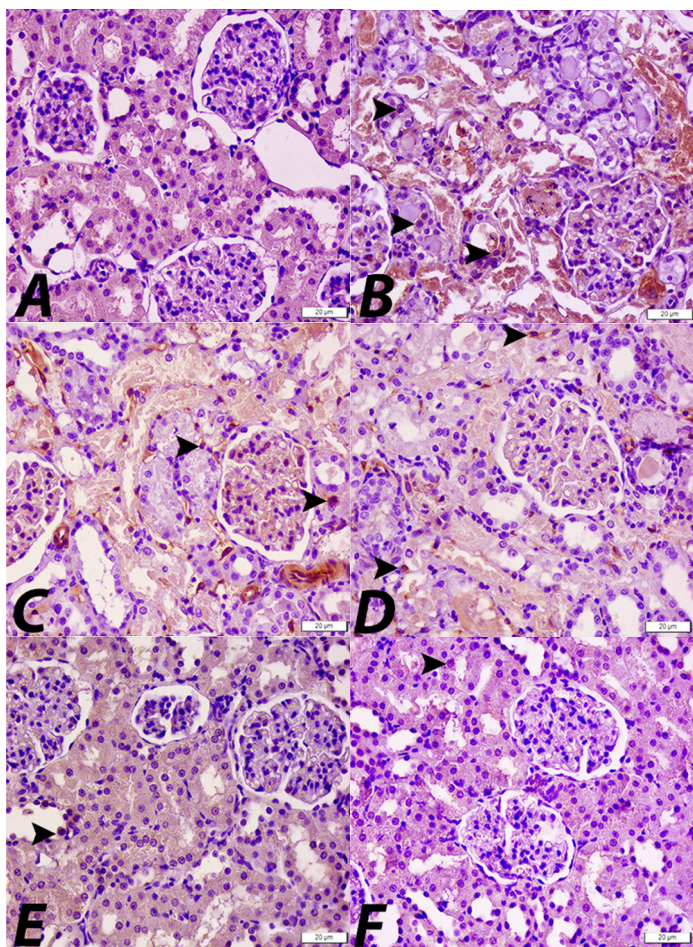


FIGURE 4. Hsp27 expressions in tubular epithelial cells (arrow heads), in the kidney tissues, Bar: 50 μm . A: Control group, B: GM group, C: GM+Hp200 group, D: GM+Hp100 group, E: Hp200 group and F: Hp100 group

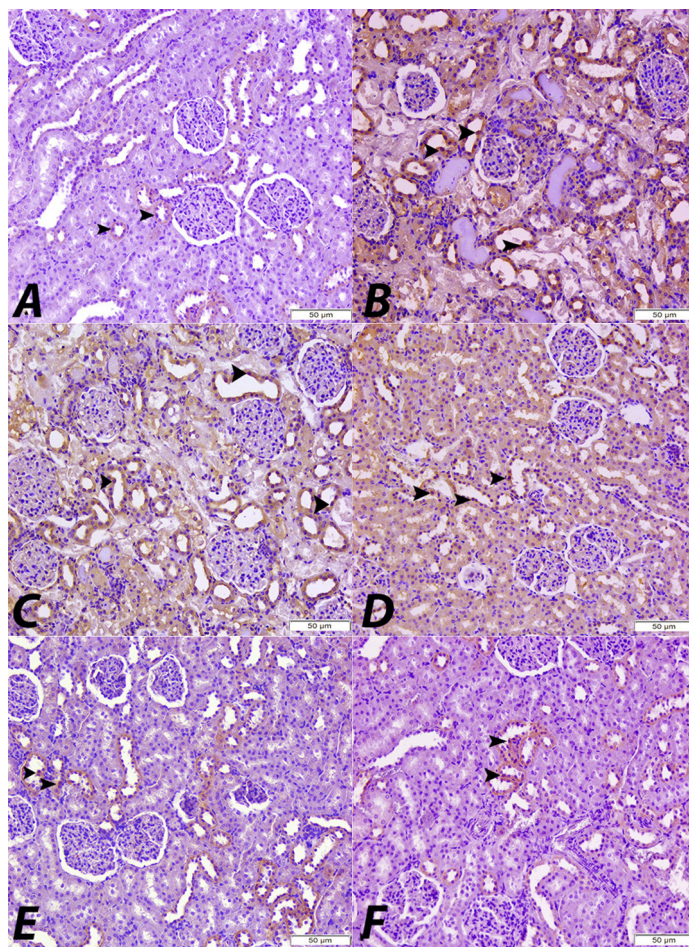


FIGURE 5. Hsp70 expressions in tubular epithelial cells (arrow heads) in the kidney tissues, Bar: 50 μm . A: Control group, B: GM group, C: GM+Hp200 group, D: GM+Hp100 group, E: Hp200 group and F: Hp100 group

compared with groups GM and GM+Hp200, and there was a statistically significant difference when compared with the GM group ($P < 0.05$).

Gentamicin (GM) is an antibiotic the most widely used in the treatment of infectious diseases caused by gram-negative and some gram-positive bacteria. Although they are preferred due to their high efficiency and cheapness [1, 2, 3], they cause serious adverse effects such as nephrotoxicity [2, 3, 4, 5, 6, 7]. The mechanism of GM-induced adverse effects is not fully understood, but there are studies showing that gentamicin increases the formation of Reactive Oxygen Species (ROS) by suppressing non-enzymatic and enzymatic antioxidants. Free radicals cause cellular injury, inflammation, degeneration, and necrosis by some mechanisms such as peroxidation of phospholipids membrane, protein denaturation, DNA damage and apoptosis [3, 12, 28]. IL-6, IL-8, and TNF- α are pro-inflammatory cytokine that they are primarily involved in the regulation of immune system, apoptosis and inflammatory responses [29].

Several studies have been reported that increasing levels of pro-inflammatory cytokines such as TNF- α [8, 11], IL-1 β [3], IL-6 [3, 30] and IL-8 [31] were positively correlated with the infiltration of inflammatory cells in both tissues of GM administered rats significantly. In the present study, we observed that IL-6, IL-8 and

TNF- α levels were increased after GM administration in kidney tissue samples.

IL-10, one of the anti-inflammatory cytokines, suppresses the inflammatory response by inhibiting the production of pro-inflammatory cytokines like TNF- α [11]. In previous studies, a significant decrease in IL-10 level was reported in treated with GM at different doses [11, 32]. In our study, it was observed that the level of IL-10 in kidney tissue decreased in GM group.

Previous histopathological studies reported that GM administration were caused nephrotoxicity [2, 4, 5, 10, 33]. The obtained kidney histopathologic results in our current study are in agreement with previous studies. In this study showed that histopathological examinations supported the biochemical effects of GM on kidney tissues.

Although many natural products such as, phytochemicals, different plants extracts and plants formulas have been used in order to stop or cure tissues damage caused by adverse effect of GS, there is still not available specific treatment. Some studies have reported that various plants extracts such as virgin coconut oil [6], Hesperidin [30], berberine [12], curcumin [8], *Malva sylvestris* extract [20], *Panax ginseng* [19], *Moringa oleifera* seed oil [3] are used for preventing or treatment the tissue damage related to GM treatment. In these

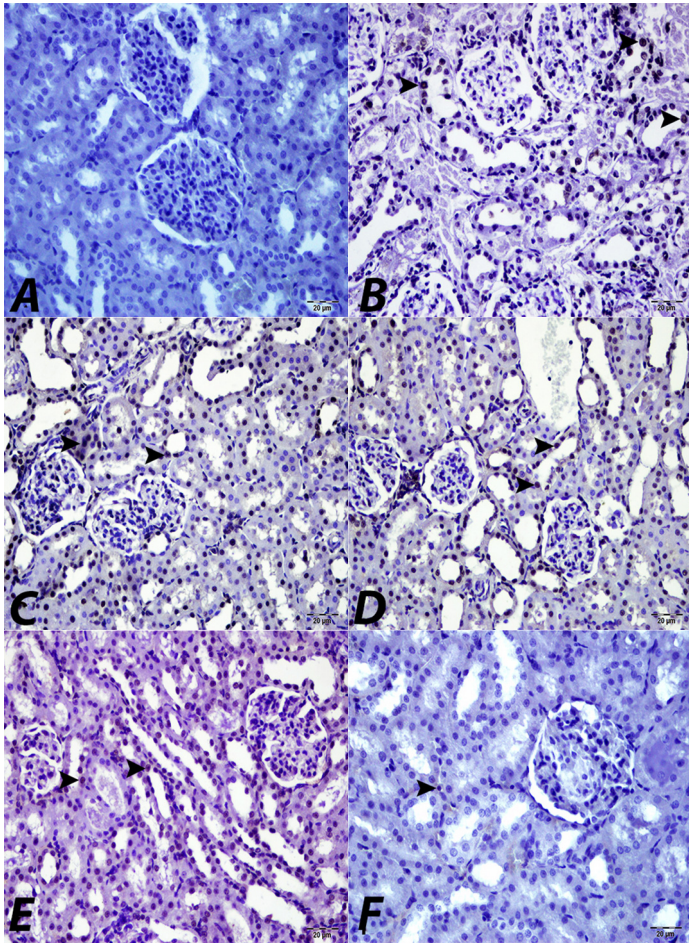


FIGURE 6. Caspase-3 expression in tubular epithelial cells (arrow heads) in kidney tissues, Bar: 50 μ m. A: Control group, B: GM group, C: GM+Hp200 group, D: GM+Hp100 group, E: Hp200 group and F: Hp100 group

studies, they reported that the severity of damage caused by GM in kidney tissues was reduced by multiple targeted therapeutic mechanisms such as prevention of oxidative stress, inflammation, and apoptosis and regulation of autophagy [8, 12, 19, 20, 30].

Helichrysum plicatum DC. (Asteraceae) is a herbaceous natural plant used traditional treatment method [21, 23, 24]. In recent years, that has been used in the treatment many diseases due to its antiapoptotic, antineurodegenerative, nephro-hepatoprotective, antihyperglycemic, antioxidant, antimicrobial properties [4, 22, 23]. The therapeutic medicinal feature of *Helichrysum* species is considered because of the presence of flavones, flavanones, flavonols, kalones, triterpenoids, and steroids [21, 23, 24].

In our previous study we reported that the adverse effects of GM on the kidney were reduced depending on the dose of Hp, histopathologically [4]. The obtained histopathologic findings in our current study are consistent with our previous studies on this subject. In previous studies different members of the *Helichrysum* species have been shown to inhibit pro-inflammatory cytokines and reduce anti-inflammatory cytokines [34, 35, 36, 37]. Nevertheless, there are no data found the role of cytokines the effect of Hp on GM induced nephrotoxicity. In the present study, it was seen GM+Hp100 treatment (100 mg·kg⁻¹ day i.p. 8 d) inhibited the kidney inflammation

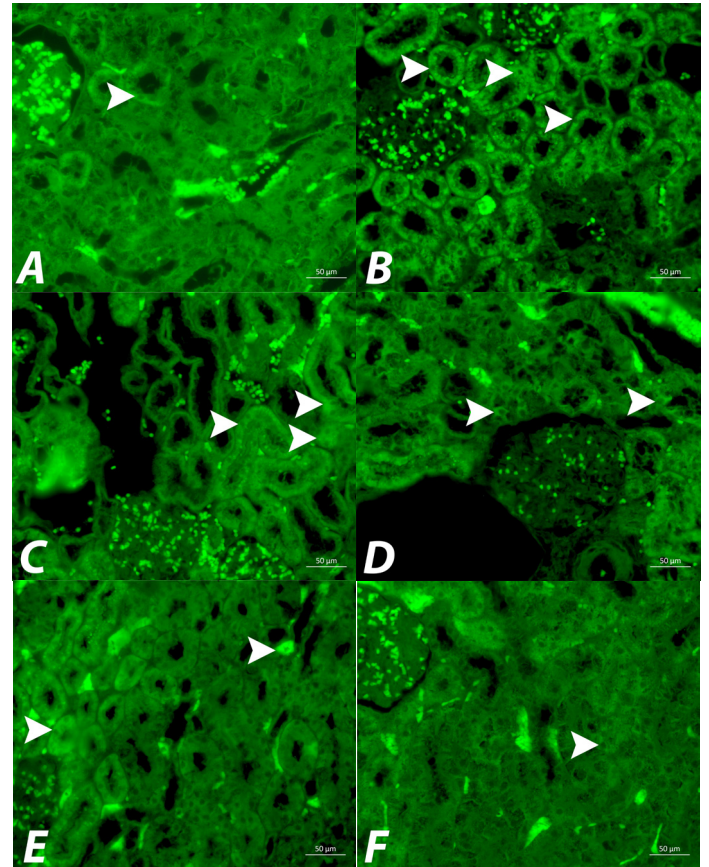


FIGURE 7. NOS expression in tubular epithelial cells (arrow heads) in the kidney tissues, Bar: 50 μ m. A: Control group, B: GM group, C: GM+Hp200 group, D: GM+Hp100 group, E: Hp200 group and F: Hp100 group

induced GM by decreasing the levels of TNF- α , IL-6, IL-8, by increasing IL-10. These results made us to think, that the protective effects of Hp on kidney damage may be due to the inhibition of inflammation.

Heat shock proteins (Hsps) are a highly conserved group of proteins produced by all living organisms that protect cells and organisms from different damage such as inflammation, exposure to toxins and oxidative stress [14, 16, 26, 38]. Hsps have been classified into six major families on the basis of their size, construction and assignment: the Hsp110, Hsp40, Hsp90, Hsp70, Hsp60 and small Hsp families including Hsp27 [16, 38]. Hsps has an important place in the intracellular and extracellular defense mechanism of kidney tissues [14, 15, 16]. In previous studies, Hsp47, Hsp72/73 [39], Hsp72 [40], Hsp90 [41] and Hsp70 [42] were detected in glomerular mesangial cells, in proximal tubular epithelial cells after GM administration. In these studies, it was reported that Hsp90 and Hsp72 levels started to increase in 36 h after GM administration compared to the control group, reached the highest level in 12 d, and started to decrease in 18 d [40, 41]. It was reported that Hsp47 expression reached its highest level on the 7th day after GM administration and decreased to the control group level on the 28th d [39]. In another study, it was reported that Hsp70 expression was more severe in the GM group compared to the control group after GM administration, but it was noted that positivity was only in the interstitial cells in both groups [43].

In our study Hsp70 and Hsp27 expressions were observed immunohistochemically in proximal, distal and collecting tubular epithelium, glomerular mesangial cells, and vascular endothelial cells in kidney tissue of the all experimental groups. In our study, it observed that Hsp70 and Hsp27 levels, which increased in kidney tissues after the GM administration, the level of decreased after the Hp (100 mg·kg⁻¹ day i.p. 8 d) treated. In our study, it observed that the Hsp27 and Hsp70 expressions were decreased in kidney tissues Group GM+Hp100 when compared with groups GM and GM+Hp200, and there was a statistically significant difference when compared with the GM group ($P < 0.05$).

Apoptosis is a physiological cellular reaction to all external and internal stimuli. The purpose of apoptosis is to destroy unwanted cells like damaged cells without giving any harm to healthy cells. The apoptotic process, can be stimulated (Bax, caspases family) or inhibited (Bcl-2 family of genes, Hsps) by different signals or cytokines [8, 10, 19, 30, 43, 44]. Previously researchers, have demonstrated that caspase-3 expression were detected increased in kidney proximal tubul epithelial and mesangial cells [6, 31, 44, 45]. The obtained kidney results in the present study were similar to mentioned studies.

To our best knowledge, the antiapoptotic effect of Hp on nephrotoxicity due to GM hasn't been studied immunohistochemically. The caspase-3 expression in kidney tissues were decreased in Group GM+Hp100 when compared with groups GM and GM+Hp200, and there was a statistically significant difference when compared with the GM group ($P < 0.05$). In our study the antiapoptotic effect of Hp (100 mg·kg⁻¹ day i.p. 8 d) on GM induced nephrototoxicity was demonstrated with caspase-3 immunohistochemically.

Nitric oxide (NO) is secreted by many cells in the body when oxidative stress increases in the body. Nitric oxide synthase (NOS) inactivates these free radicals and eliminates the negative effects of oxidative stress on the body. In some gentamicin toxicity studies on kidney tissues [45, 46, 47], it has been reported that gentamicin administration increases the NOS expression level in the body. Some studies have shown that Hp inhibits oxidative damage by suppressing oxidative stress in the body. In an experimental study, it has been shown that Hp suppresses the oxidative stress that occurs after gentamicin administration and protects the tissues against damage in tissues and organs [4, 48]. In this study, it was observed that gentamicin administration increased NOS expressions by increasing oxidative damage in kidney tissues, in accordance with the literature. Again, it was determined that Hp application suppressed oxidative stress and protected tissues against gentamicin toxication against gentamicin applications.

All of our results showed that Hp (100 mg·kg⁻¹ day) reduced the levels of pro-inflammatory cytokines such as IL-8, IL-6, and TNF- while increasing the level of anti-inflammatory cytokine IL-10. It was also observed that Hp reduced the expressions of the apoptotic marker caspase-3, NOS and Heat shock proteins such as Hsp27 and Hsp70. During the evaluation of the results of the study, it was observed that high doses of *Helichrysum plicatum* may also have slightly adverse effects on kidney tissues.

CONCLUSION

As a conclusion, we have shown that Hp probably due to its chemical properties has a protective effect against GM-induced nephrotoxicity by reducing the values stated above to normal values. However, in the future, comprehensive studies are needed to elucidate the mechanism of Hp's nephroprotective effect.

Conflict of interest

The Authors declare that there is no conflict of interest.

BIBLIOGRAPHICS REFERENCES

- [1] Becker B, Cooper MA. Aminoglycoside Antibiotics in the 21st Century. ACS. Chem. Biol. [Internet]. 2013; 8(1):105-15. doi: <https://doi.org/f4jnqm>
- [2] Jado JC, Humanes B, González-Nicolás MÁ, Camaño S, Lara JM, López B, Emilia C, García-Bordas J, Tejedor A, Lazaro A. Nephroprotective Effect of Cilastatin against Gentamicin-Induced Renal Injury *In Vitro* and *In Vivo* without Altering Its Bactericidal Efficiency. Antioxidants [Internet]. 2020; 9(9):821. doi: <https://doi.org/gq5x84>
- [3] Edeogu CO, Kalu ME, Famurewa AC, Asogwa NT, Onyeji GN, Ikpemo KO. Nephroprotective Effect of *Moringa Oleifera* Seed Oil on Gentamicin-Induced Nephrotoxicity in Rats: Biochemical Evaluation of Antioxidant, Anti-inflammatory, and Antiapoptotic Pathways. J. Am. Coll. Nutr. [Internet]. 2020; 39(4):307-315. doi: <https://doi.org/ghj22w>
- [4] Apaydin Yildirim B, Kordali S, Terim Kapakin KA, Yildirim F, Aktas Senocak E, Altun S. Effect of *Helichrysum plicatum* DC. subsp. *plicatum* ethanol extract on gentamicin-induced nephrotoxicity in rats. J. Zhejiang Univ. Sci. B. [Internet]. 2017; 18:501-511. doi: <https://doi.org/gt5kh4>
- [5] Medić B, Stojanović M, Rovčanin B, Kekić D, Škodrić SR, Jovanović GB, Vujović KS, Divac N, Stojanović R, Radenković M, Prostan M. Pioglitazone attenuates kidney injury in an experimental model of gentamicin-induced nephrotoxicity in rats. Sci. Rep. [Internet]. 2019; 9:13689. doi: <https://doi.org/gmq9z2>
- [6] Famurewa AC, Maduagwuna EK, Folawiyo AM, Besong EE, Eteudo AN, Famurewa OA, Fidelis EE. Antioxidant, anti-inflammatory, and antiapoptotic effects of virgin coconut oil against antibiotic drug gentamicin-induced nephrotoxicity via the suppression of oxidative stress and modulation of iNOS/NF- κ B/caspase-3 signaling pathway in Wistar rats. J. Food Biochem. [Internet]. 2020; 44(1):e13100. doi: <https://doi.org/gmdxg4>
- [7] Ince S, Kucukkurt I, Demirel HH, Arslan-Acaroz D, Varol N. Boron, a Trace Mineral, Alleviates Gentamicin-Induced Nephrotoxicity in Rats. Biol. Trace Elem. Res. [Internet]. 2020; 195(2):515-524. doi: <https://doi.org/gt5kh5>
- [8] Galaly SR, Ahmed OM, Mahmoud AM. Thymoquinone and Curcumin Prevent Gentamicin-Induced Liver Injury by Attenuating Oxidative Stress, Inflammation and Apoptosis. J. Physiol. Pharmacol. [Internet]. 2014 [cited 12 Jan. 2024]; 65(6):823-832. Available in: <https://goo.su/OJFZ0B7>
- [9] Arjinajarn P, Chueakula N, Pongchaidecha A, Jaikumkao K, Chatsudthipong V, Mahatheeranont S, Orranuch N, Nipon C, Anusorn L. Anthocyanin-rich Riceberry bran extract attenuates gentamicin-induced hepatotoxicity by reducing oxidative stress, inflammation and apoptosis in rats. Biomed. Pharmacother. [Internet]. 2017; 92:412-420. doi: <https://doi.org/gbt6bb>

- [10] Khaksari M, Esmaili S, Abedloo R, Khastar H. Palmatine ameliorates nephrotoxicity and hepatotoxicity induced by gentamicin in rats. *Arch. Physiol. Biochem.* [Internet]. 2021; 127(3):273–278. doi: <https://doi.org/gt5kh6>
- [11] Ali FEM, Hassanein EHM, Bakr AG, El-Shoura EAM, El-Gamal DA, Mahmoud AR, Abd-Elhamid TH. Ursodeoxycholic acid abrogates gentamicin-induced hepatotoxicity in rats: Role of NF- κ B-p65/TNF- α , Bax/Bcl-xl/Caspase-3, and eNOS/iNOS pathways. *Life Sci.* [Internet]. 2020; 254:117760. doi: <https://doi.org/gt5kh7>
- [12] Adil M, Kandhare AD, Dalvi G, Ghosh P, Venkata S, Raygude KS, Bondhankar SL. Ameliorative effect of berberine against gentamicin-induced nephrotoxicity in rats via attenuation of oxidative stress, inflammation, apoptosis and mitochondrial dysfunction. *Ren. Fail.* [Internet]. 2016; 38(6):996–1006. doi: <https://doi.org/gmq9xj>
- [13] Helal MG, Zaki MMAF, Said E. Nephroprotective effect of saxagliptin against gentamicin-induced nephrotoxicity, emphasis on anti-oxidant, anti-inflammatory and anti-apoptotic effects. *Life Sci.* [Internet]. 2018; 208:64–71. doi: <https://doi.org/gd6wcn>
- [14] Kalmar B, Greensmith L. Induction of heat shock proteins for protection against oxidative stress. *Adv. Drug. Deliv. Rev.* [Internet]. 2009; 61(4):310–318. doi: <https://doi.org/cwkf8q>
- [15] Chebotareva N, Bobkova I, Shilov E. Heat shock proteins and kidney disease: perspectives of HSP therapy. *Cell Stress Chaperones* [Internet]. 2017; 22(3):319–343. doi: <https://doi.org/f98bbc>
- [16] Ikwegbue PC, Masamba P, Oyinloye BE, Kappo AP. Roles of Heat Shock Proteins in Apoptosis, Oxidative Stress, Human Inflammatory Diseases, and Cancer. *Pharmaceuticals* [Internet]. 2018; 11(1):2. doi: <https://doi.org/gt5kh8>
- [17] Gouda SAA, Aboulhoda BE, Abdelwahed OM, Abdallah H, Rashed L, Hussein RE, Sharawy N. Low-intensity pulsed ultrasound (LIPUS) switched macrophage into M2 phenotype and mitigated necroptosis and increased HSP 70 in gentamicin-induced nephrotoxicity. *Life Sci.* [Internet]. 2023; 314:121338. doi: <https://doi.org/gt5kh9>
- [18] Le TA, Hiba T, Chaudhari D, Preston AN, Palowsky ZR, Ahmadzadeh S, Shekoohi S, Cornett EM, Kaye AD. Aminoglycoside-Related Nephrotoxicity and Ototoxicity in Clinical Practice: A Review of Pathophysiological Mechanism and Treatment Options. *Adv. Ther.* [Internet]. 2023; 40(4):1357–1365. doi: <https://doi.org/gtn572>
- [19] Kalkan Y, Kapakin KAT, Kara A, Atabay T, Karadeniz A, Simsek N, Karakus E, Can I, Yildirim S, Ozkanlar S, Sengul E. Protective effect of *Panax ginseng* against serum biochemical changes and apoptosis in kidney of rats treated with gentamicin sulphate. *J. Mol. Histol.* [Internet]. 2012; 43:603–613. doi: <https://doi.org/gt5kjb>
- [20] Mohamadi Yarijani Z, Najafi H, Shackebaei D, Madani SH, Modarresi M, Jassemi SV. Amelioration of renal and hepatic function, oxidative stress, inflammation and histopathologic damages by *Malva sylvestris* extract in gentamicin induced renal toxicity. *Biomed. Pharmacother.* [Internet]. 2019; 112:108635. doi: <https://doi.org/gt5kjc>
- [21] Akaberi M, Sahebkar A, Azizi N, Emami SA. Everlasting flowers: Phytochemistry and pharmacology of the genus *Helichrysum*. *Ind Crops Prod.* [Internet]. 2019; 138:111471. doi: <https://doi.org/gt5kjd>
- [22] Jovanović M, Drnić Z, Bigović D, Alimpić-Aradski A, Duletić-Laušević S, Šavikin K. *In vitro* and *in silico* predictions of antineurodegenerative properties of *Helichrysum plicatum* flower extract. *Lekovite Sirovine.* [Internet]. 2020; 40(1):45–51. doi: <https://doi.org/gt5kjj>
- [23] Vujić B, Vidaković V, Jadranin M, Novaković I, Trifunović S, Tešević V, Mandić B. Composition, Antioxidant Potential, and Antimicrobial Activity of *Helichrysum plicatum* DC. *Plants* [Internet]. 2020; 9(3):337. doi: <https://doi.org/gt5kjk>
- [24] Güneş A, Kordali Ş, Turan M, Usanmaz Bozhüyük A. Determination of antioxidant enzyme activity and phenolic contents of some species of the Asteraceae family from medicinal plants. *Ind. Crops Prod.* [Internet]. 2019; 137:208–213. doi: <https://doi.org/gt5kjh>
- [25] Iskender H, Dokumacioglu E, Terim Kapakin KA, Bolat I, Mokhtare B, Hayirli A, Yenice G. Effect of Oleanolic acid administration on hepatic AMPK, SIRT-1, IL-6 and NF- κ B levels in experimental diabetes. *J. Diabetes Metab. Disord.* [Internet]. 2023; 22:581–590. doi: <https://doi.org/gt5kjl>
- [26] Kapakin KAT, Sahin M, Buyuk F, Kapakin S, Gursan N, Saglam YS. Respiratory tract infection induced experimentally by *Ornithobacterium rhinotracheale* in quails: effects on heat shock proteins and apoptosis. *Rev. Méd. Vét.* 2013; 164(3):132–140.
- [27] Dokumacioglu E, Iskender H, Yenice G, Kapakin KAT, Sevim C, Hayirli A, Saral S, Comakli S. Effects of astaxanthin on biochemical and histopathological parameters related to oxidative stress on testes of rats on high fructose regime. *Andrologia* [Internet]. 2018; 50(7):e13042. doi: <https://doi.org/gmt9jz>
- [28] Jaikumkao K, Pongchaidecha A, Thongnak L, Wanchai K, Arjinajarn P, Chatsudthipong V, Chattipakorn N, Lungkaphin A. Amelioration of Renal Inflammation, Endoplasmic Reticulum Stress and Apoptosis Underlies the Protective Effect of Low Dosage of Atorvastatin in Gentamicin-Induced Nephrotoxicity. *Plos One* [Internet]. 2016; 11(10):e0164528. doi: <https://doi.org/f9rt92>
- [29] Fielding CA, McLoughlin RM, McLeod L, Colmont CS, Najdovska M, Grail D, Ernst A, Jones SA, Topley N, Jenkins BJ. IL-6 Regulates Neutrophil Trafficking during Acute Inflammation via STAT3. *J. Immunol.* [Internet]. 2008; 181(3):2189–2195. doi: <https://doi.org/f3v2xb>
- [30] Subramanian P, Anandan R, Jayapalan JJ, Hashim OH. Hesperidin protects gentamicin-induced nephrotoxicity via Nrf2/HO-1 signaling and inhibits inflammation mediated by NF- κ B in rats. *J. Funct. Foods* [Internet]. 2015; 13:89–99. doi: <https://doi.org/f64px2>
- [31] Muthuraman A, Singla SK, Rana A, Singh A, Sood S. Renoprotective Role of Flunarizine (Mitochondrial Permeability Transition Pore Inactivator) against Gentamicin induced Nephrotoxicity in rats. *Yakugaku Zasshi* [Internet]. 2011; 131(3):437–443. doi: <https://doi.org/b7n52p>
- [32] Balakumar P, WitnessKoe WE, Gan YS, JemayPuah SM, Kuganesswari S, Prajapati SK, Varatharajan R, Jayachristy SA, Sundram K, Bahari MB. Effects of pre and post-treatments with dipyrindamole in gentamicin-induced acute nephrotoxicity in the rat. *Regul. Toxicol. Pharmacol.* [Internet]. 2017; 84:35–44. doi: <https://doi.org/gf4557>

- [33] Aboubakr M, Abdelazem AM. Hepatoprotective effect of aqueous extract of cardamom against gentamicin induced hepatic damage in rats. *Int. J. Basic Appl. Sci.* [Internet]. 2016; 5(1):1-4. doi: <https://doi.org/gt5kjk>
- [34] Antunes Viegas D, Palmeira-de-Oliveira A, Salgueiro L, Martinez-de-Oliveira J, Palmeira-de-Oliveira R. *Helichrysum italicum*: From traditional use to scientific data. *J. Ethnopharmacol.* [Internet]. 2014; 151(1):54-65. doi: <https://doi.org/f5rt8q>
- [35] Kim YJ, Seok JH, Cheung W, Lee SN, Jang HH, Bae S, Le H. Effects of *Helichrysum bracteatum* flower extracts on UVB irradiation-induced inflammatory biomarker expression. *Biomed. Dermatol.* [Internet]. 2019; 3(1):9. doi: <https://doi.org/gt5kjm>
- [36] De Canha MN, Komarnytsky S, Langhansova L, Lall N. Exploring the Anti-Acne Potential of Impepho [*Helichrysum odoratissimum* (L.) Sweet] to Combat *Cutibacterium acnes* Virulence. *Front Pharmacol.* [Internet]. 2020; 10:1559. doi: <https://doi.org/gt5kjin>
- [37] Kherbache A, Senator A, Laouicha S, Al-Zoubi RM, Bouriche H. Phytochemical analysis, antioxidant and anti-inflammatory activities of *Helichrysum stoechas* (L.) Moench extracts. *Biocatal. Agric. Biotechnol.* [Internet]. 2020; 29:101826. doi: <https://doi.org/gt5kjp>
- [38] Archana PR, Aleena J, Pragna P, Vidya MK, Abdul Niyas PA, Bagath M, Krishnan G, Manimaran A, Beena V, Kurien EK, Veerasamy S, Bhatta R. Role of Heat Shock Proteins in Livestock Adaptation to Heat Stress. *J. Dairy Vet. Anim. Res.* [Internet]. 2017; 5(1):13-19. doi: <https://doi.org/gt5kjq>
- [39] Cheng M, Razzaque MS, Nazneen A, Taguchi T. Expression of the heat shock protein 47 in gentamicin-treated rat kidneys. *Int. J. Exp. Pathol.* [Internet]. 1998; 79(3):125-132. doi: <https://doi.org/dsgw28>
- [40] Wang Z, Liu L, Mei Q, Liu L, Ran Y, Zhang R. Increased Expression of Heat Shock Protein 72 Protects Renal Proximal Tubular Cells from Gentamicin-induced Injury. *J. Korean Med. Sci.* [Internet]. 2006; 21(5):904-910. doi: <https://doi.org/b8gcfh>
- [41] Ohtani H, Wakui H, Komatsuda A, Satoh K, Miura AB, Itoh H, Tashima Y. Induction and intracellular localization of 90-kilodalton heat-shock protein in rat kidneys with acute gentamicin nephropathy. *Lab. Invest.* 1995; 72(2):161-165. PMID: 7853850.
- [42] Yamamoto S, Nakano S, Owari K, Fuziwara K, Ogawa N, Otaka M, Tamaki K, Watanabe S, Komatsuda A, Wakui H, Sawada K, Kubota H, Itoh H. Gentamicin inhibits HSP70-assisted protein folding by interfering with substrate recognition. *FEBS Lett.* [Internet]. 2010; 584(4):645-651. doi: <https://doi.org/fb45f7>
- [43] Abdelrahman RS, Abdelmageed ME. Renoprotective effect of celecoxib against gentamicin-induced nephrotoxicity through suppressing NF κ B and caspase-3 signaling pathways in rats. *Chem. Biol. Interact.* [Internet]. 2020; 315:108863. doi: <https://doi.org/gt5kjr>
- [44] Abd-Elhamid TH, Elgamal DA, Ali SS, Ali FEM, Hassanein EHM, El-Shoura EAM, Hemeida RAM. Reno-protective effects of ursodeoxycholic acid against gentamicin-induced nephrotoxicity through modulation of NF- κ B, eNOS and caspase-3 expressions. *Cell Tissue Res.* [Internet]. 2018; 374(2):367-387. doi: <https://doi.org/gfjhjs>
- [45] Christo JS, Rodrigues AM, Mouro MG, Cenedeze MA, Simões MJ, Schor N, Higa EMS. Nitric oxide (NO) is associated with gentamicin (GENTA) nephrotoxicity and the renal function recovery after suspension of GENTA treatment in rats. *Nitric Oxide* [Internet]. 2011; 24(2):77-83. doi: <https://doi.org/bk64f3>
- [46] Dawood AF, Maarouf A, Alzamil NM, Momenah MA, Shati AA, Bayoumy NM, Kamar SS, Haidara MA, ShamsEldeen AM, Yassin HZ, Hewett PW, Al-Ani B. Metformin Is Associated with the Inhibition of Renal Artery AT1R/ET-1/iNOS Axis in a Rat Model of Diabetic Nephropathy with Suppression of Inflammation and Oxidative Stress and Kidney Injury. *Biomedicines* [Internet]. 2022; 10(7):1644. doi: <https://doi.org/gt5kjs>
- [47] Antar S, Al-Karmalawy AA, Mourad A, Mourad M, Elbadry M, Saber S, Khodir A. Protective Effects of Mirazid on Gentamicin-induced Nephrotoxicity in Rats through Antioxidant, Anti-inflammatory, JNK1/iNOS, and Apoptotic Pathways; Novel Mechanistic Insights. *Pharm. Sci.* [Internet]. 2022; 28(4):525-540. doi: <https://doi.org/gt5kjt>
- [48] Aslan M, Deliorman Orhan D, Orhan N, Sezik E, Yesilada E. *In vivo* antidiabetic and antioxidant potential of *Helichrysum plicatum* ssp. *Plicatum* capitulum in streptozotocin-induced-diabetic rats. *J. Ethnopharmacol.* [Internet]. 2007; 109(1):54-59. doi: <https://doi.org/bjfw45>