
Prediction of the individual response to treatment of skeletal Class II malocclusions and their long-term stability. A Case Report.

*Sergio Duarte-Inguanzo^{1,2}, Aurora Duarte-López³, Olga Zambrano⁴
and Jesús A. Luengo-Ferreira⁵*

¹ Unidad Académica de Odontología, Universidad Autónoma de Zacatecas, Ciudad de Zacatecas, México.

² División de Estudios para Graduados, Facultad de Odontología, Universidad del Zulia. Maracaibo, Venezuela.

³ Facultad de Odontología Unidad Saltillo, Maestría en Ortodoncia, Universidad Autónoma de Coahuila, México.

⁴ Instituto de Investigaciones, Facultad de Odontología, Universidad del Zulia. Maracaibo, Venezuela.

⁵ Unidad Académica de Odontología, Universidad Autónoma de Zacatecas, Ciudad de Zacatecas, México.

Keywords: Class II; Herbst appliance; Baccetti and Franchi model.

Abstract. Non-surgical correction of class II skeletal malocclusions begins at an early age, during the growth and development of the jaw. Treatments tend to be relatively long and generate financial commitments for the family. Predicting the success and stability of the results can be helpful for parents who wish to know about the prognosis and make the right decision to start treatment. This work reports the findings of the prediction of the response to treatment of a skeletal class II malocclusion and its long-term stability in a thirteen-year-old male patient. The individual prediction cephalometric model of Baccetti and Franchi was applied. According to this indicator, the treatment of this patient would result in “a great response”. The patient was treated with a Herbst-type fixed mandibular anterior projection appliance, followed by brackets for the final detailing of the occlusion. Sixteen years later, after finishing treatment, the correction of the Class II malocclusion, the overbite and the harmony in the profile with the projection of the mandible forwards are maintained by the increase in the total mandibular length (13 mm), and through the opening of the angle between the ramus and mandibular body from 122° to 128°. In conclusion, the individual prediction cephalometric model applied, particularly in this case report, allowed us to accurately predict the excellent response and stability of the facial, dental and skeletal results of the class II skeletal malocclusion treatment.

Predicción de la respuesta al tratamiento de las maloclusiones Clase II esqueléticas y su estabilidad a largo plazo. Presentación de un caso.

Invest Clin 2024; 65 (3): 369 – 377

Palabras clave: cefalometría; aparato de Herbst, Modelo de Baccetti y Franchi.

Resumen. La corrección no quirúrgica de las maloclusiones esqueléticas clase II se inicia en las edades tempranas, durante el crecimiento y desarrollo de la mandíbula, suelen ser tratamientos relativamente largos y generar compromisos financieros para la familia. Predecir el éxito y la estabilidad de los resultados puede resultar útil a los padres que desean saber sobre el pronóstico y tomar la decisión para iniciar el tratamiento. Este trabajo reporta los hallazgos de la predicción de la respuesta al tratamiento de una maloclusión clase II esquelética y su estabilidad a largo plazo, en un paciente masculino, de trece años de edad. Se aplicó el modelo cefalométrico de predicción individual de Baccetti y Franchi, y según este indicador, el tratamiento tendría “*una gran respuesta*”. El paciente fue tratado con un aparato de proyección anterior mandibular fijo tipo Herbst y apliques ortodóncicos para el detallado final de la oclusión. Dieciséis años después de finalizado el tratamiento, se mantuvo la corrección de la maloclusión Clase II, la sobremordida horizontal y la armonía en el perfil con la proyección de la mandíbula hacia adelante, mediante el aumento de la longitud total mandibular (13 mm), y por medio de la apertura del ángulo entre rama y cuerpo mandibular de 122° a 128°. En conclusión, el modelo cefalométrico de predicción individual aplicado particularmente en este reporte de caso permitió predecir de manera acertada la buena respuesta y estabilidad de los resultados faciales, dentales y esqueléticos del tratamiento de la maloclusión esquelética clase II.

Received: 28-01-2024

Accepted: 13-05-2024

INTRODUCTION

Class II malocclusion or skeletal distocclusion significantly impacts function and facial aesthetics. The prevalent diagnostic finding in this type of malocclusion is mandibular skeletal retrusion, which is challenging to treat and has a high risk of relapse.¹

Various functional/orthopedic devices for treating this malocclusion, among which the Herbst and the Twin-Block, stand out and have shown remarkable effectiveness². In a systematic review, Cozza *et al.* reported substantial variabilities in the results of class

II treatments attributed to the type of device used, duration of treatment, patient cooperation, time of intervention, and the inherent characteristics of the patient³. Similarly, Canut and Arias report that patients' response to this malocclusion treatment varies significantly. Moreover, the nature of the variations that induce the resolution of Class II with functional devices is still unclear⁴. Petrovic *et al.*, in addition to other authors, affirm that the effects of Class II therapy are much more effective when carried out during the peak of mandibular growth⁵⁻⁷. Saadia and Valencia report that if the therapy is applied

when biological events occur during growth and craniofacial development processes, it will have a more effective impact and less tendency to relapse⁸. The success in treating skeletal malocclusions is determined by the extent to which the correction is stable in the long term^{8,9}. Al Yami *et al.* reported variable results between good and moderate stability in 10-year post-treatment follow-ups¹⁰. Likewise, Bondemark *et al.*, in a study on the post-treatment stability of Class II orthopedic therapies with Herbst-type appliances in patients who received the treatment during the pubertal growth peak, reported good stability regarding facial characteristics; however, they found recurrence regarding the molar and canine relationship¹¹.

Ruf and Pancherz report that the correction of skeletal Class II is more effective if the Herbst appliance is combined with multibracket treatment; in this way, a more significant occlusal correction is achieved, and they report stability for two years' post-treatment¹². Tulloch *et al.* reported that in younger patients treated, less recurrence was observed than in those who received treatment at an older age¹³. Failure can occur individually to different treatments and similar protocols, even in patients who receive treatment under ideal conditions^{8,9}. The possibility of predicting with greater certainty the prognosis of the results of a skeletal Class II treatment and its long-term stability could be an invaluable tool for the clinician.

Previous studies have tried to find specific predictors to anticipate a successful treatment; however, they have yet to be systematically validated¹⁴⁻¹⁶. Some authors affirm that a Class II patient at the peak of pubertal growth with a closed gonial angle of the mandible will react successfully to functional orthopedic treatment^{7,17}. In this regard, Baccetti and Franchi proposed a cephalometric model to predict individually the response to treatment of a skeletal Class II malocclusion with functional jaw orthopedics. They analyzed various cephalometric

parameters, noting that only the angular relationship between the ramus and the mandibular body represents the indicator with predictive power¹⁸.

This work aimed to report the prediction of the response to treatment of a skeletal Class II malocclusion and its long-term stability using the Baccetti and Franchi cephalometric model¹⁸.

CASE PRESENTATION

This is the case of a 13-year-old male patient who attended the orthodontic service at the Piezzo Dental Clinic in Zacatecas, Mexico. Informed consent to participate in the study was obtained from the patient and his representatives, and the authorization to publish his photograph in this study. He presented with no medical history of interest, euryprosopic facial type, a symmetrical, slightly enlarged lower facial third, convex profile, short chin-neck distance, lip incompetence, open nasolabial angle, and closed mentolabial angle (Fig. 1a). Permanent dentition, Class II molar and bilateral canine, 14 mm overjet, and 30% overbite. A triangular symmetric upper dental arch; square asymmetric lower arch, upper and lower crowding; a severe curve of Spee (Fig. 2a); and cervical vertebral maturation stage CS3¹⁹.

The cephalometric analysis determined a skeletal Class II mandibular hypoplasia²⁰ (Fig. 3a). The value of the predictive angular measurement (Co-Go-Me°) was 122°; therefore, according to the model, the patient would have a "great response" to treatment¹⁸ (Fig. 4).

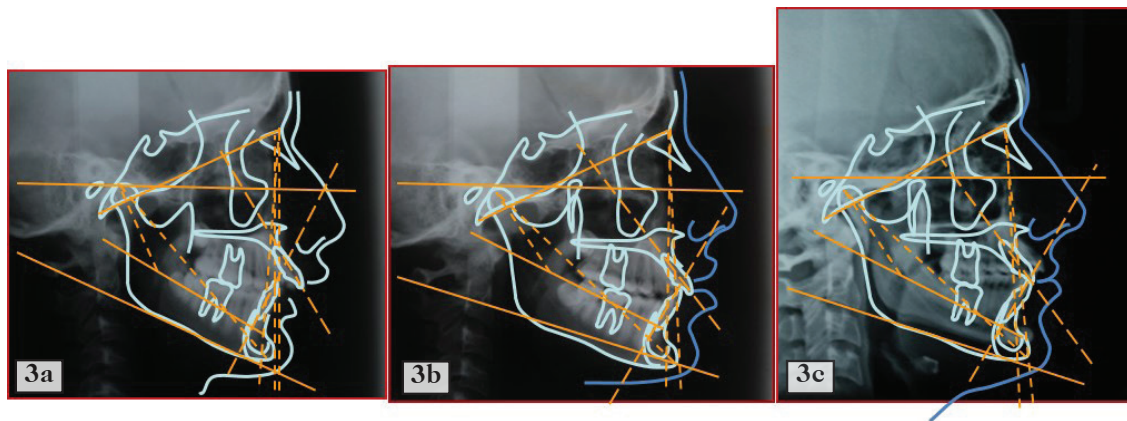
The patient was treated with a fixed Herbst-type mandibular anterior projection appliance with bands for one year and five months to position the mandible in a molar and canine Class I (Fig. 2b) and a straight profile until the end of the mandibular growth peak CS4 and the beginning of CS5¹⁹, at 14 years and eight months of age (Fig. 1b). In the second phase, complete brackets were placed for one year, and Class



Fig. 1. Front and profile photographs: (1a) pre-treatment at 13 years and three months of age; (1b) after Herbst therapy at 14 years and eight months of age; (1c) at the end of bracket treatment at 15 years and eight months of age; (1d) 16 years after treatment completion at 31 years and nine months of age.

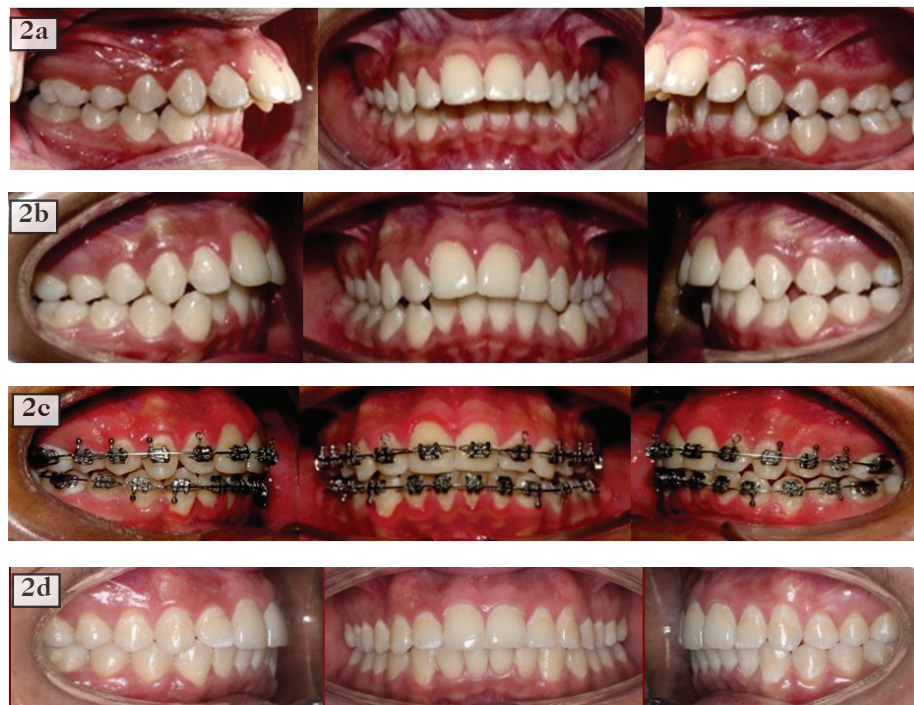

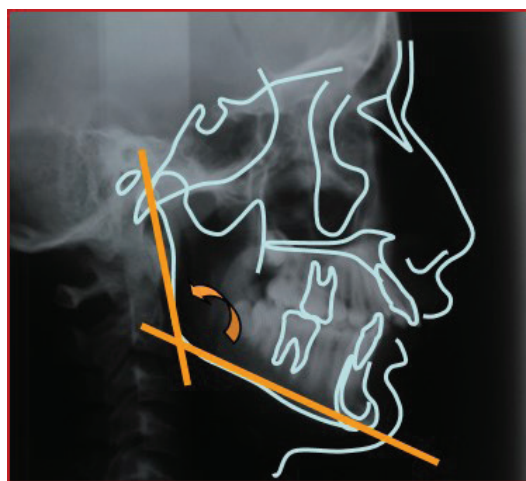Fig. 2. Intraoral photographs, Right Lateral, Frontal, and Left Lateral Views: (2a) Pre-treatment at 13 years and three months of age; (2b) after Herbst therapy at 14 years and eight months of age; (2c) at the end of bracket treatment at 15 years and eight months of age; (2d) 16 years after treatment completion at 31 years and nine months of age.



Cephalometric Measurements	Norma	Initial pre-treatment measurement (3a)	End of treatment measurement (3b)	16 years post-treatment (3c)
Convexity (A/B-Pg)	2mm	9mm	1mm	-1mm
Maxillary Deepness (PoOr-NaA)	90°	89°	89°	90°
Facial Deepness (Po-Or/N-Pg)	87°	75°	86°	88°
Mandibular Plane (Go-Me/Po-Or)	26°	30°	27°	29°
Upper Incisor / N-A	22°	25°	25°	23°
Lower Incisor / Mandibular Plane	90°	84°	89°	92°
Mandibular Arch (De-XI/XI-Pm)	29°	34°	28°	30°
Mandibular Body Length(XI-Pm)	69 mm	67 mm	68mm	70mm
Total Mandibular Length (Co-Gn)	132mm	121mm	131mm	134mm

Fig. 3. (3a) Initial Cephalometry; (3b) After treatment; (3c) 16 years post-treatment...



Favorably Response

Co-Go-Me 122°

The measure of the prediction was 122°, 2° below 124°, which means it will have a great response to treatment.

Fig. 4. Tracing of the Condylion, Gonion, Menton (Co-Go-Me) planes to form the predictive angle according to Baccetti and Franchi's individual prediction cephalometric model.

II intermaxillary ligatures were used for four months (Fig. 2c). The profile and facial harmony were further improved at the end of this phase (Fig. 1c). Finally, a containment period was carried out for one year with Hawley-type removable retainers, worn 24 hours a day for six months, followed by six months of only night use, and the patient was discharged. Appointments were held every three years to monitor the stability of the results.

Intraorally, the molar and canine Class II changed to Class I (Fig. 2c). Post-treatment cephalometry, in general terms, showed a remarkable correction of skeletal Class II and harmonization in profile²⁰. Most notable was the 6° increase in angulation between the ramus and the mandibular body, thus increasing the total mandibular length by 10 mm (Fig. 3b).

At the age of 31 years, new records were taken: extra orally, greater harmony was observed in the facial contour, proportioned thirds, and straight and balanced profile (Fig. 1d). Intra orally, a Class I molar and canine occlusion with solid interdigitation on both sides, 2 mm overjet, and 30% overbite were observed (Fig. 2d).

Cephalometrically, a relevant value was the increase in total mandibular length of 3 mm in these 16 years after finishing the

treatment, thus maintaining a balanced profile²⁰ (Fig. 3c).

A superimposition shows us that 16 years after treatment, the total mandibular length alone increased by 3 mm more, reaching a total increase of 13 mm since the beginning of treatment (Fig. 5).

DISCUSSION

This paper reports the prediction of the response to treatment and its long-term stability by applying the Baccetti and Franchi¹⁸ model in an adolescent with skeletal class II malocclusion, treated with a Herbst-type fixed appliance and the use of brackets for the final detailing of the occlusion.

The study by Baccetti and Franchi¹⁸ identified the Co-Go-Me angle with a predictive power of 80.4% reliability. According to this model, a Co-Go-Me angle between 124° and 128.5° will respond favorably to orthopedic therapy; a Co-Go-Me angle greater than 128.5° will react unfavorably to therapy; and those patients who initially present a Co-Go-Me angle of less than 124° will have a great response to treatment; however, these authors did not present long-term stability results. In the present report, this measure (122°) correctly predicted the largely favorable response to treatment.

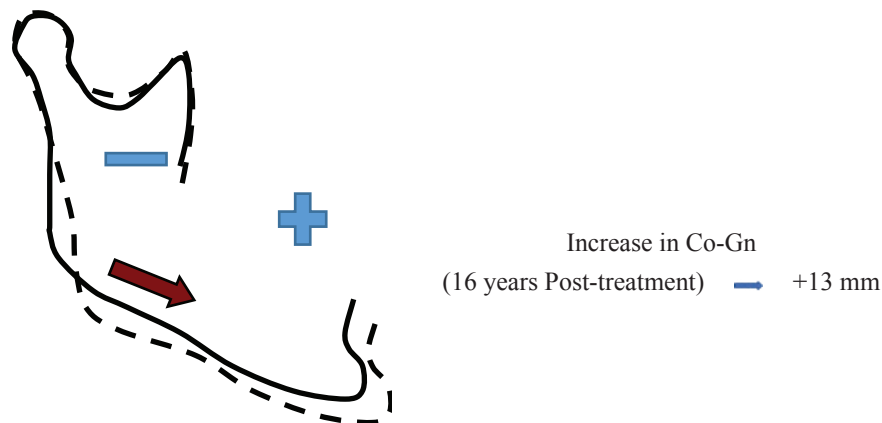

Fig. 5. Superimposition of the mandible (Continuous line: 13 years three months of age - Dotted line: 31 years nine months of age).

This prediction model determines that the shape of the mandible, specifically the angular relationship between the ramus and the body, plays a more critical role as an indicator of treatment prognosis than the position of the mandible in relation to other craniofacial structures. Other authors report similar findings^{14,15}.

Van Limborgh and Enlow²¹ described that the mandible has growth control with a more significant genetic load than the maxilla; therefore, there is less possibility of changes under environmental influences. However, the rotations between the ramus and mandibular body and the redirection of condylar growth are susceptible to changes determined by environmental factors or therapeutic actions²¹. In skeletal Class II malocclusion due to mandibular hypoplasia, the therapeutic solution is the elongation of the mandible to bring forward its body and the chin, and this can be achieved by generating, with the treatment, a descending intra-matrix rotation between the ramus and the mandibular body; that is, opening precisely the angle between these two structures, consequently increasing the distance between the condyle and the chin, and therefore increasing the total mandibular length². So, if the mandible initially presents an open angle between the ramus and the body, the prognosis could be unfavorable, since it would have less possibility of opening further and lengthening the mandible forward (it is as if a hinge were opening). Therefore, it is necessary that this angle initially be closed⁵.

Cozza *et al.* suggest that a closed mandibular angle before treatment correlates with evidence of better responsiveness to orthopedic treatment to increase total mandibular length and vice versa. At the start of treatment, a patient with an open angle between the ramus and the mandibular body will be less likely to attain elongation through orthopedic therapy³. Likewise, Petrovic *et al.* state that the potential responsiveness to orthopedic therapy aimed at stimulating growth in the mandibular con-

dyle is significantly more significant in the presence of anterior growth rotation of the mandible than in a posterior growth rotation⁵. In the case of the current study, the patient initially presented a significantly closed Co-Go-Me mandibular angle and a notable anterior rotation of the mandible. On the other hand, Proffit and Saadia define a good response to orthopedic therapy as one that is maintained in the long term^{8,9}. Canut *et al.* state that there is a high risk of recurrence in skeletal Class II treatments; however, in some cases, it is possible to maintain stable long-term favorable treatment results, free of recurrence and containment⁴.

In the case described in this report, after completing the comprehensive treatment, the patient only used removable retainers for one year with discontinuous use over time. The remaining time, the patient remained free of containment and relapse.

Ruf and Pancherz report good results in occlusal correction and stability of the treatment of skeletal Class II; they attribute this to the simultaneous application of full bracket and Herbst appliances¹². In the patient of the present report, occlusal correction and excellent stability were achieved by combining complete brackets and Herbst. Ruf and Pancherz¹² made the stability evaluation two years after treatment, unlike in the case presented in this report, where the evaluation was performed 16 years after finishing the treatment.

Bondemark reports post-treatment stability in facial characteristics but not in occlusion or cephalometric data¹¹. The present report maintained favorable facial, dental, and cephalometric changes; moreover, a better and more detailed occlusal interdigitation was achieved with time. This refinement was self-formed. Likewise, the facial profile reached a better balance and harmony, so it can be inferred that growth and development alone have the capacity for self-improvement in cases like this when they are helped at a specific moment through a treatment that creates a suitable scenario.

Tulloch *et al.* state that the earlier the age at which treatment is started, the more stable it will be, and vice versa¹³. This statement sounds somewhat ambiguous since they do not mention the specific age. In our case, Herbst therapy was started at the beginning of the CS3¹⁹ mandibular growth peak.

In conclusion, Baccetti and Franchi's prediction model for Class II malocclusion correction predicted the response to treatment in this particular patient, which was confirmed and resulted in long-term stable facial and dental skeleton changes.

ACKNOWLEDGMENT

We thank Dr. Humberto Martínez for his contribution to editing and translating the manuscript and Carlos E. Duarte-Hernández for searching bibliographic references.

Funding

This study was not funded.

Conflicts of interest

The authors reported no potential conflict of interest.

Authors' ORCID number

- Sergio Duarte-Inganzo (SD): 0009-0008-7877-5574
- Aurora Duarte-López (AD): 0009-0005-0386-1046
- Olga Zambrano (OZ): 0000-0003-4867-2351
- Jesús A. Luengo-Ferreira (JL): 0000-0002-2780-5496

Authors' contribution

SD: Treatment and clinical and radiographic follow-up of the case. Conception,

design, analysis, and interpretation of data, editing, review, and approval of the final version of the manuscript to be published. Funding support. AD: Analysis and interpretation of data, editing, review, and approval of the final version to be published. OZ: Conception, design, analysis, and interpretation of data, editing, critical review, and approval of the final version to be published. JL: Analysis and interpretation of data, critical review, and approval of the final version to be published.

REFERENCES

1. **Enlow D.** Crecimiento Maxilofacial 1993 Edt. McGraw Hill.
2. **McNamara JA, Bookstein F.** Skeletal and dental changes following functional therapy on class II patients. *Am J Orthod* 2009;88:91-110.
3. **Cozza P, Baccetti T, Franchi L, De Toffol L, McNamara JA Jr.** Mandibular changes produced by functional appliances in Class II malocclusion: a systematic review. *Am J Orthod Dentofacial Orthop.* 2006;129(5): 599.e1-12.
4. **Canut J, Arias S.** Evaluación a largo plazo de evolución de tratamientos de maloclusiones división 2 Clases II. *Eur J Orthod* 2000;21:377-386.
5. **Petrovic A, Stutzmann J, Lavergne J.** Mechanism of craniofacial growth and modus operandi of functional appliances: a cell-level and cybernetic approach to orthodontic decision making. In: Carlson DS, ed. *Craniofacial Growth Theory and Orthodontic Treatment.* Ann Arbor, Mich: Center for Human Growth and Development, The University of Michigan; 1990:13-74. *Craniofacial Growth Monograph Series; Monograph 23.*
6. **Hägg U, Pancherz H.** Dentofacial orthopaedics in relation to chronological age, growth period and skeletal development. An analysis of 72 male patients with Class II division 1 malocclusion treated with the Herbst appliance. *Eur J Orthod.* 1988;10:169-176.

7. **Faltin K, Faltin RM, Baccetti T, Franchi L, Ghiozzi B, McNamara Jr JA.** Long-term effectiveness and treatment timing, *Angle Orthod* 2009;73:221-230.
8. **Saadia M, Valencia R:** *Dentofacial Orthopedics in the Growing Child; Understanding Craniofacial Growth in the management of Malocclusions.* Edt. Wiley Blackwell, 2022.
9. **Proffit W, Fields H.** *Ortodoncia Contemporánea.* Elsevier, 2019; 87-91
10. **Al Yami EA, Kuijpers-Jagtman A, van't Hof M.** Stability of orthodontic treatment outcome: follow-up until 10 years postretention. *Am J Orthod Dentofacial Orthop* 1999;115(3):300-304.
11. **Bondemark L, Holm A, Hansen K, Axelson S, Mohlin B, Brattstrom V, Paulin G, Pietila T.** Long-term stability of orthodontic treatment and patient satisfaction. A systematic review. *Angle Orthod* 2007;77(1):181-191.
12. **Ruf S, Pancherz H.** Herbst/multibracket appliance treatment of Class II division 1 malocclusions in early and late adulthood: a prospective cephalometric study of consecutively treated subjects. *Eur J Orthod* 2006;28:352-360.
13. **Tulloch JF, Phillips C, Koch G, Proffit W.** The effects of early intervention on skeletal pattern Class II malocclusion: a randomized clinical trial. *Am J Orthod Dentofacial Orthop* 1997;111(4):391-400.
14. **Charron C.** Recherche d'éléments pronostiques quant a l'efficacité de l'Activateur en occlusion de classe II d'Angle. *Orthod Fr.* 1989;60:685-693.
15. **Cretella E, Franchi L, Gastaldi G, Giuntini V, Lione R, Cozza P, Pavoni C.** Development of a prediction model for short-term success of functional treatment of Class II malocclusion. *Int J Environ Res Public Health* 2020;17(12):4473.
16. **Ahlgren J, Laurin C.** Late results of activator treatment: a cephalometric study. *Br J Orthod.* 1976;3:181-187.
17. **Patel HP, Moseley HC, Noar JH.** Cephalometric determinants of successful functional appliance therapy. *Angle Orthod.* 2002;72:410-417.
18. **Baccetti T, Franchi L.** Cephalometric mandibular features for the prediction of individual outcomes of Class II treatment including functional jaw orthopedics. *Am J Orthod Dentofacial Orthop* 2012;43(7):112-128.
19. **Baccetti T, Franchi L.** The Cervical Vertebral Maturation (CVM) method for the assessment of optimal treatment timing in dentofacial orthopedics. *Semin Orthod* 2005;11(3):119-129.
20. **Duarte S.** *Atlas de Cefalometría. Análisis clínico y práctico.* Ed. Amolca, 2003:119-147.
21. **Van Limborgh F, Enlow D.** Rotations and increase mandibular, genetic appearance. *Angle Orthod* 1997;23:112-145.